



## Musculoskeletal and Joint Manifestations in Type II Diabetes Mellitus

Kamath Surendra Umesh\* and Ranganatha Y.P.

Kasturba Medical College Hospital, Attavar, Mangalore, Manipal University, Manipal, Karnataka, India

Date of Receipt- 25/12/2014  
Date of Revision- 05/01/2015  
Date of Acceptance- 16/01/2015

### Address for Correspondence

Kasturba Medical College Hospital,  
Attavar, Mangalore,  
Manipal University,  
Manipal, Karnataka,  
India.

E-mail: [skamath3@hotmail.com](mailto:skamath3@hotmail.com)

### ABSTRACT

**Objective:** Incidence of diabetes and life expectancy in these patients has increased resulting in increased prevalence of musculoskeletal problems in diabetic patients. Musculoskeletal complications related to diabetes are common and can lead to severe morbidity. These complications may be due to metabolic or microvascular causes. Increased prevalence of these connective tissue disorders in the recent times has affected the quality of life for these patients. This study was carried out with aim to find the prevalence and types of rheumatological manifestations in patients having type 2 Diabetes mellitus.

**Patients and Methods:** A total of 150 patients with Type 2 diabetes mellitus were chosen randomly in this cross sectional study with inclusion criteria of disease duration for minimum of 1 year. Those patients who were too ill, willing to participate and with inflammatory arthritis were excluded. Data was analysed using SPSS software version 17.

**Results:** A total of 150 subjects were assessed for various musculoskeletal manifestations. A total of 46 subjects amounting to about 30.66% had the manifestation. The age ranged from 20 to 76 years with a mean age of 51.8 years. The duration of diabetes was of less than 5 years in 8 patients and was of more than 5 years in 38 patients

**Conclusions:** From the above observation it is clear that about 29% suffer from rheumatological manifestations with most common seen in knee and shoulder joint.

**Keywords:** Musculoskeletal complications, Diabetes mellitus, Osteoarthritis, Frozen shoulder.

## INTRODUCTION

Diabetes mellitus is a metabolic condition characterized by persistent hyperglycemia with resultant morbidity and mortality related primarily to its associated microvascular and macrovascular complications<sup>1</sup>. Type 2 Diabetes mellitus is a highly prevalent disorder worldwide. India is popularly known as a “diabetes capital of the world”. Diabetes can affect the individuals by the disease per se as well as the complications that occur over the period of years. Important and common complications include neuropathy, nephropathy and retinopathy.

Musculoskeletal complications related to diabetes are common and can lead to severe morbidity.

Consequences following diabetic complication are, muscle infarction, neuropathic arthropathy, Charcot joint<sup>2</sup>.

Metabolic derangements, can lead to diffuse idiopathic skeletal hyperostosis (DISH) and osteopenia. DISH is not only associated with Type 2 diabetes mellitus but also seen in patients with obesity, hyperuricaemia and dyslipidaemia. Syndromes due to microvascular disease carpal tunnel syndrome, Dupuytren’s contracture, flexor synovitis, Adhesive capsulitis, limited joint mobility. Other complication like Sclerodactyly, Calcific Tendinitis of Shoulder, Periarthritis of Shoulder, Reflex Sympathetic Dystrophy<sup>2,3</sup>. longer duration of diabetes, especially with poor glycemic control, increase the risk of developing many of the mentioned complications. Connective tissue disorders, neuropathy, vasculopathy and combinations may result in musculoskeletal complications in diabetic patients. The development of musculoskeletal problems depends on age and duration of diabetes. Early recognition and treatment will increase the quality of life in these patients.

This study was conducted with aim to find the proportion and type of musculoskeletal and joint manifestations in patients having Type 2 Diabetes mellitus.

## PATIENTS AND METHODS

This study was done at teaching hospitals attached to Kasturba Medical College Mangalore, Karnataka .South India, after getting clearance from the Institutional Ethical Committee.

A total of 150 patients with Type 2 diabetes mellitus were selected randomly from inpatients and outpatients attending the departments of Medicine and Orthopaedics. Inclusion criteria considered all the patients with Type 2 diabetes mellitus who attended hospital Outpatient and in patients.

Also those patients with the history of diabetes for minimum of 1 year were included.

Exclusion criteria included the patients who were too ill to be interviewed and examined, those unwilling to participate and patients with inflammatory arthritis. A detailed history and clinical examination was undertaken in each patient with emphasis on musculoskeletal examination after obtaining a written informed consent. Data was recorded in a proforma. Physical examination was focused on hand and shoulder abnormalities.

The presence of carpal tunnel syndrome was defined as pain and paraesthesia of the first, second, and third fingers, plus a positive Tinel’s or Phalen’s sign. Dupuytren’s disease was diagnosed in patients with palpable thickening of the palmar fascia, with flexor deformity of the second, third, fourth, or fifth fingers. Flexor tenosynovitis was diagnosed by feeling a nodule with locking phenomenon during extension or flexion of any fingers. Adhesive capsulitis of the shoulder was

diagnosed when unilateral shoulder present for over 3 months and the range of external rotation and active and passive shoulder movements in all planes was less than 50% of normal. Past history of any surgery for any of these disorders was also considered.

Data collected was analysed using SPSS software version 17.

## RESULTS

A total of 150 subjects with diabetes of >1yr duration were examined for various musculoskeletal manifestation. A total of 43 subjects amounting to about 28.66% had the manifestation (Figure 1). The age ranged from 20 to 76 years with a mean age of 51.8 years.

In this study more number of women are examined compared to men with more positive results in women. Total numbers of women were 85 and men were 65 in this study. Duration of diabetics for less than 5 years was in 5 patients and 38 patients had diabetes duration for more than 5 years

The most common findings were osteoarthritis and frozen shoulder, interestingly these are seen diabetics of more than 5 year duration and some subjects had multiple manifestation causing overlap of numbers. More than one musculoskeletal manifestation was seen in 12 patients. Prevalence of musculoskeletal disorders in the study population included Frozen shoulder in 18, Dupuytren's contracture in 6, Osteoarthritis 22 and Trigger finger 0 (Figure 2).

The duration of diabetes also had a key role in various manifestations and its severity as 38 patients out of 43 had diabetes lasting for more than 5 years.

## DISCUSSION

Musculoskeletal complication involving hand and shoulder was common in diabetic patients. In this study the most

common findings were frozen shoulder, osteoarthritis and dupuytren's contracture; these were seen in diabetic females.

In this study out of 150 subjects, 43(28.66%) were having manifestations compared to Ashish *et al* around 42.58%.

The most common manifestation in this study was osteoarthritis of knee (50%), this is same as study done by ashish *et al* .the finding was confirmed by asking the history and duration of pain in the joint. Second most common finding is frozen shoulder which is commonly seen in diabetic woman. These cause more painful debilitating restriction of joint movement. Studies done earlier shown similar results.

Duration of diabetes more commonly strongly associated with microangiopathic complication, most of the symptomatic subjects are of >5 yrs. duration these findings are also seen in studies done by Ashish *et al* and Cagliero *et al*<sup>4,5</sup>. In this study numbers more women were affected comparing with the men. The other manifestation like carpal tunnel syndrome, Charcot joints were not seen during examination of subjects.

Pathogenesis of adhesive capsulitis, dupuytren's contracture and flexor tenosynovitis not understood, glucose induced collagen modifications might be an important component of this syndrome. Adhesive capsulitis of shoulder is thought to be due to fibrosis and inflammation.

Diabetes can induce fibrosis by altering proliferative characteristics of several cell types and increased expression of cytokines<sup>6-9</sup>.

## CONCLUSION

From the above observation it is clear that about 29% of the type 2 diabetics suffer from rheumatological manifestations. The most common manifestations are seen in knee and shoulder joint.

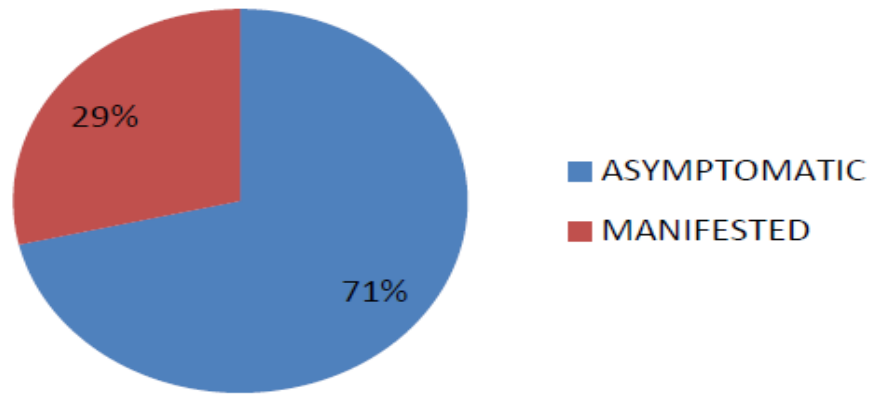
From this study it could be concluded that thorough examination of musculoskeletal system should be made a part of physical examination in diabetics. So life style modification and exercises to various joints should be part of diabetic management.

### ACKNOWLEDGEMENTS

Authors would like to thank help and support from KMC Mangalore and Manipal University in performing this study.

### REFERENCES

1. Diabetes and musculoskeletal manifestations (Editorial) *J Indian Rheumatol Assoc* 2003 Nov 23:11:13 ([www.medind.nic.in](http://www.medind.nic.in))
2. Smith LL, Burnet SP and McNeil JD, Musculoskeletal manifestations of diabetes mellitus, *Br J Sports Med* 2003;37: 30-35
3. Fauci AS, Braunwald E, Isselbacher KJ, Wilson JD, Martin JB, Kasper DL, Harrison's Principles of Internal Medicine, 17th edition McGraw Hills, Health Professional Division; 2008.
4. Mathew AJ, Nair JB and Pillai SS. Rheumatic- usculoskel *et al* manifestations in type 2 Diabetes mellitus patients in south India. *International Journal of Rheumatic Diseases* 2011;14: 55-60.
5. Cagliero E, Apruzzese W, Perlmutter GS, Nathan DM, .Musculoskeletal Disorders of the Hand and Shoulder in Patients with Diabetes Mellitus *Am J Med* 2002;112 : 543-7
6. Crispin JC and Alcocer-Varela J. Rheumatologic manifestations of diabetes mellitus *Am J Med* 2003; 114:753-7.
7. Abate M, Schiavone C, Salini V. Sonographic evaluation of the shoulder in asymptomatic elderly subjects with diabetes. *BMC Musculoskeletal Disord*. 2010; 7:11:278.
8. Sattar MA and Luqman WA. Periarthritis: another duration related complication of diabetes mellitus. *Diabetes Care*; 1985; 8:507-510.
9. Parada-Turska J, Majdan M. The musculoskeletal system in diabetic patients. *Postepy Hig Med Dosw (Online)*. 2005; 59:236-44.



**Figure 1.** Prevalence of musculoskeletal manifestations.

Diagnosis	No of subjects
Frozen shoulder	18
Dupuytren’s contracture	6
Osteoarthritis	22
Trigger finger	0

**Figure 2.** Prevalence different types of musculoskeletal manifestations.