

Multiple Pancreaticoduodenal Penetrating Gunshot Trauma Evolving into Acute Necrotizing Pancreatitis. A Combined Surgical and Minimally Invasive Approach

Mario Testini¹, Giuseppe Piccinni¹, Pasquale Pedote², Germana Lissidini¹, Angela Gurrado¹,
Domenica Lardo¹, Luigi Greco³, Rinaldo Marzaioli¹

¹Section of General and Thoracic Surgery, Department of Applications in Surgery of Innovative Technologies; ²Department of Radiology; ³Section of General Surgery, Department of Emergency and Organ Transplantation. University Medical School of Bari. Bari, Italy

ABSTRACT

Context Shotgun injuries are the cause of increasing surgical problems related to the proliferation of firearms. Gunshot pancreaticoduodenal traumas are unusual in urban trauma units. Their management remains complex because of the absence of standardized, universal guidelines for treatment and the high incidence of associated lesions of major vessels as well as of other gastrointestinal structures. Surgical treatment is still controversial, and the possibilities offered by the safe and effective mini-invasive techniques seem to open new, articulated perspectives for the treatment of pancreaticoduodenal injury complications.

Case report We present the case of a 27-year-old man with multiple penetrating gunshot trauma evolving into acute necrotizing pancreatitis, treated by combining a surgical with a mini-invasive approach. At admission, he presented a Glasgow Coma Score of 4 due to severe hemorrhagic shock. First, surgical hemostasis, duodenogastric resection, multiple intestinal resections, peripancreatic and thoracic drainage were carried out as emergency procedures. On the 12th postoperative day, the patient underwent re-surgery with toilette, external duodenal drainage with Foley tube and peripancreatic

drainage repositioning as a result of a duodenal perforation due to acute necrotizing pancreatitis. Eight days later, following the accidental removal of the peripancreatic drains, a CT scan was done showing a considerable collection of fluid in the epiploon retrocavity. Percutaneous CT-guided drainage was performed by inserting an 8.5 Fr pigtail catheter, thus avoiding further re-operation. The patient was successfully discharged on the 80th postoperative day.

Conclusions The treatment of multiple pancreaticoduodenal penetrating gunshot traumas should focus on multidisciplinary surgical and minimally invasive treatment to optimize organ recovery.

INTRODUCTION

Shotgun injuries, although rare in the European Union, are the cause of increasing surgical problems related to the proliferation of firearms, civilian crime and terrorism in peace time [1, 2], and may lead to severe trauma disease and even to death, usually due to hemorrhagic shock. Prognosis is significantly worse in the presence of multi-organ injuries [3]. Gunshot pancreaticoduodenal injuries are relatively unusual, but not rare in urban trauma units. Their

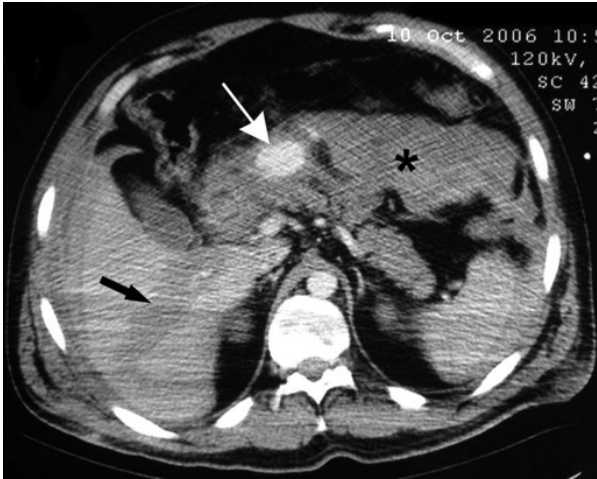

Figure 1. CT scan: active hemorrhage by lesion of pancreatic-duodenal artery (white arrows), liver laceration (black arrow) and hemoperitoneum (*).

management remains complex because of the absence of standardized, universal guidelines for treatment [4], and the high incidence of associated lesions of major vessels and of other gastrointestinal structures [5]. Therefore, surgical treatment is still controversial, ranging from primary sutures to pancreaticoduodenectomy [6].

The possibilities offered by safe and effective mini-invasive techniques seem to open new, articulated perspectives for the treatment of pancreaticoduodenal injury complications, such as fluid collection and pancreatitis [7, 8]. We present the case of a patient with multiple penetrating gunshot trauma evolving into

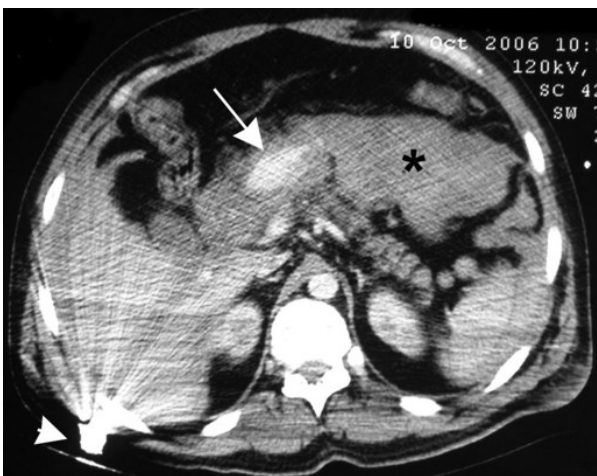

Figure 2. CT scan shows retained firearm bullet (arrow head) which caused: hemorrhage by lesion of pancreatic-duodenal artery (white arrows), liver laceration (black arrow) and hemoperitoneum (*).

acute necrotizing pancreatitis, treated by combining a surgical with a mini-invasive approach.

CASE REPORT

A 27-year-old man was evaluated in the emergency room for multiple penetrating abdominal, thoracic and cranio-facial gunshot injuries. At admission, he presented a Glasgow Coma Score of 4 due to severe hemorrhagic shock. A total-body CT scan revealed maxillo-ethmoidal fractures with a detained projectile, bilateral massive hemothorax and large pulmonary contusions, with a bullet in the spinal canal at level of T3, and multiple costal and scapular fractures. A diffuse hemoperitoneum, a large intrahepatic hematoma of the right lobe with liver laceration and an active bleeding lesion of the pancreatic-duodenal artery were evident (Figure 1). Moreover, two bullets were observed in the posterior abdominal wall (Figure 2) and in the pelvic floor, respectively.

The emergency laparotomy confirmed the massive hemoperitoneum and revealed diffused bile spillage, a large intracapsular hematoma of the right lobe of the liver, a hematoma of the pancreatic head, a jejunal perforation 2 cm from the Treitz ligament, and further small bowel (Figure 3) and mesenteric perforations. Moreover, the superior flexure of the duodenum was perforated, and a laceration of the duodenal

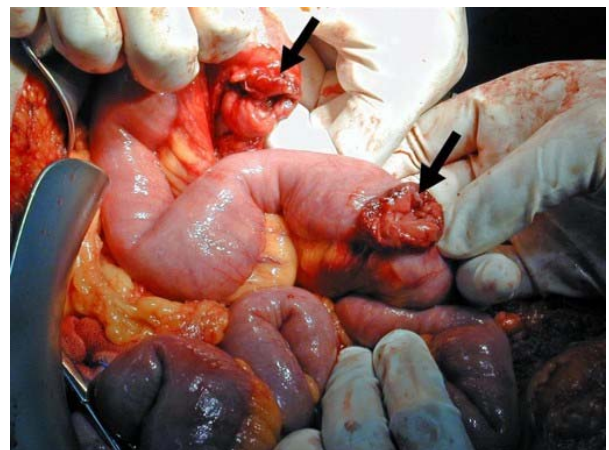


Figure 3. Emergency laparotomy: two small bowel perforations (black arrows) are shown.

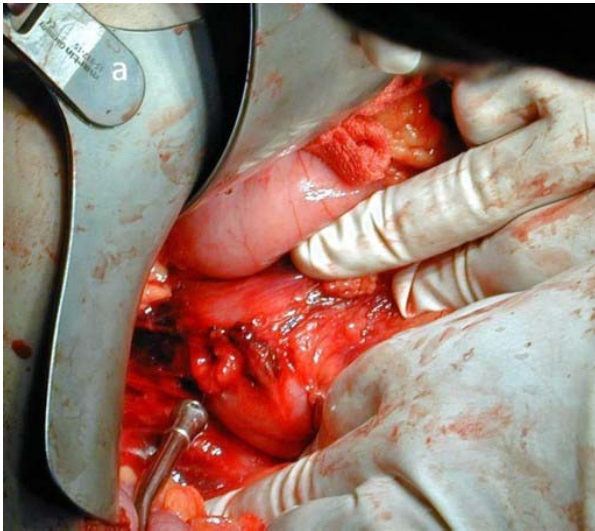


Figure 4. Emergency laparotomy: a wide laceration of the inferior flexure of the duodenum is shown.

inferior flexure was evident (Figure 4). Liver mobilization with inspection of the intracapsular hematoma and a wide Kocher maneuver with a primary two-layer closure of the duodenal laceration were performed. Hemostatic suture of the superior branches of the pancreaticoduodenal artery was necessary in order to stop the bleeding causing the hemoperitoneum. A Billroth II procedure with a gastroenteroanastomosis constructed with a jejunal loop of 60 cm from the Treitz ligament and a distal Braun enteroenteroanastomosis were performed. A jejunal resection was also required, and a mechanical jejunojejunal terminolateral anastomosis was constructed 2 cm below the Treitz ligament with an EEA 25 stapler (Ethicon, Cincinnati, OH, U.S.A.). Two abdominal drains in proximity of the duodenal stump and the Treitz ligament, and one pelvic drain were positioned. Double thoracic drainage and removal of the bullet from the ethmoidal cells were also carried out.

In the immediate postoperative period, a CT scan and neurosurgical re-evaluation showed a severe nervous lesion at the level of the T3 causing paraplegia, secondary to the bullet retained in the spinal canal. Owing to prolonged ventilation, a tracheostomy had to be performed on the 6th postoperative day. Perioperative intravenous fluids and colloids, antibiotics including cefalosporin, metronidazole and aminoglycoside, total parenteral

nutrition and inhibitor of the pancreatic secretion were administered.

On the 12th postoperative day, bilioenteric fluid was observed from the right drainage tube; a CT scan showed perihepatic and perisplenic fluid collection extending into the pancreatic space; laboratory investigation revealed leucocytosis and increased serum levels of amylases, lipases and bilirubin. The same high values were demonstrated in the fluid collected from the drainage tube.

Re-laparotomy showed a considerable amount of peritoneal exudate in the peripancreatic region; the head and body of the pancreas were involved in a massive inflammatory process producing wide areas of necrosis (Figure 5). Inflammatory disease consistent with pancreatitis involved the duodenal stump, with a discontinuance measuring 1 cm in diameter and located 2 cm forward of the stapler suture. All the anastomoses were undamaged and well healed. A clearing of the pancreatic space was performed; a Foley catheter (n. 14), secured by a tobacco bag suture, was inserted through the duodenal perforation (Figure 6) and three drainage tubes were positioned.

On the 6th postoperative day, the patient was extubated from mechanical ventilation; two days later, following the accidental removal of two peripancreatic drains, fever, leucocytosis and abdominal distension

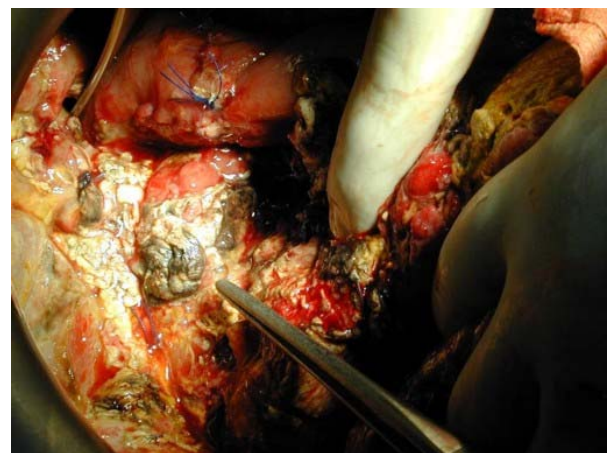


Figure 5. Emergency re-laparotomy: the pancreatic head (indicated by the tips of a dissection forceps) and body (depressed by the finger of the surgeon) are involved in a massive inflammatory process producing wide areas of necrosis.

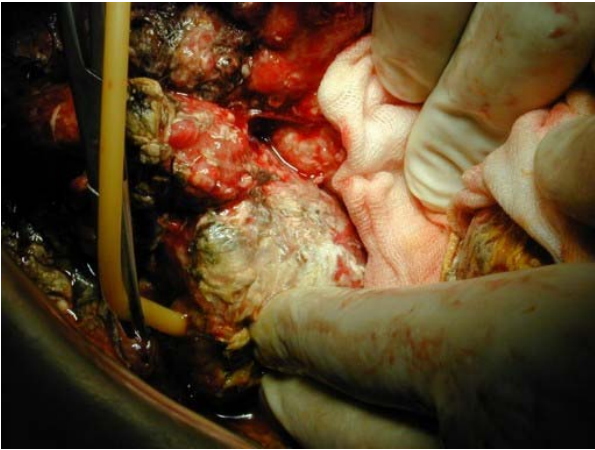

Figure 6. Emergency re-laparotomy: a Foley catheter is inserted through the duodenal perforation.

appeared. A CT scan showed a considerable and moderately homogeneous fluid collection (15-25 Hounsfield units) in the epiploic retrocavity (Figure 7); consequently, percutaneous CT-guided drainage was performed by inserting an 8.5 Fr pigtail catheter with one-shot technique (Figure 8). *Pseudomonas aeruginosa* and *Staphylococcus haemolyticus* bacteria infected the pancreatic juice collected by the percutaneous drainage, confirming the diagnosis of infected necrotizing acute pancreatitis.

Two days later the patient with tracheostomy was moved from the intensive care unit to our surgical unit. As the postoperative period continued, the acute necrotizing pancreatitis

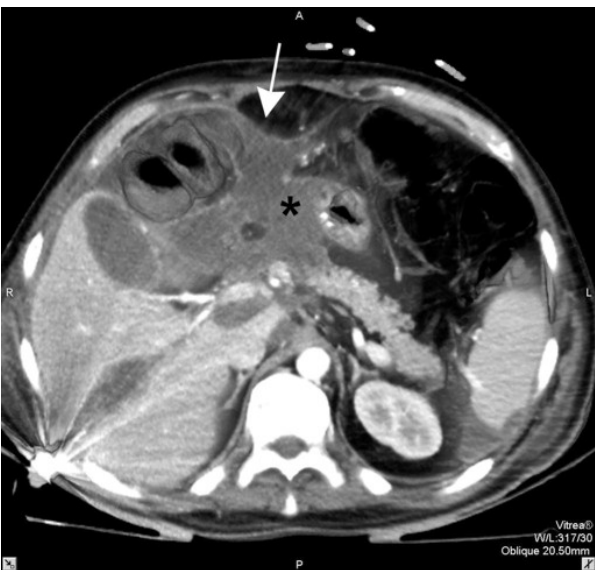

Figure 7. CT scan: peripancreatic fluid collections (*) reaching the anterior abdominal wall (arrow).

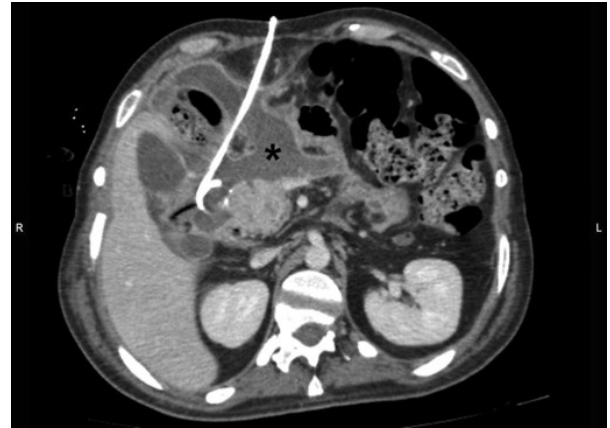


Figure 8. CT guidance percutaneous 10 French pigtail drainage was positioned into the fluid collection (*).

evolved into a pancreatic fistula with an initial mean output of 350 mL/day which was treated by conservative management (Figure 9). Thirty-nine days after re-surgery, the tracheostomy was closed and, six days later, the patient started a light diet; the Foley in the duodenum was removed 58 days after its insertion, and the patient was discharged 80 days after the gunshot trauma. Two months after the complete resolution of the pancreatic fistula, the pigtail catheter was removed (Figure 10). Eighteen months later the patient is well despite paraplegia.

DISCUSSION

An incidence of penetrating injuries in the pancreas, ranging from 1 to 12%, has been reported in the literature; combined

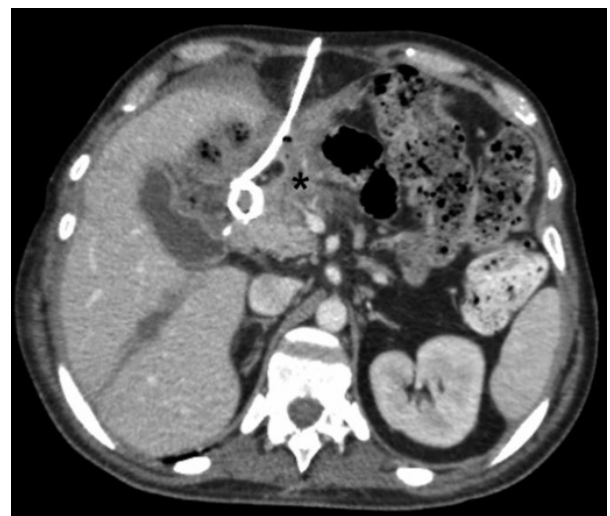

Figure 9. After 15 days with the catheter in place, the fluid collection (*) has diminished in size.

pancreaticoduodenal lesions are rare and account for less than 10% of pancreatic injuries [9, 10]. Gunshot wounds of the duodenum and pancreas cause most pancreaticoduodenal injuries [5].

Duodenal and pancreatic traumas are associated with a variety of other serious lesions in 45-85% of cases [11, 12] and overall morbidity and mortality ranging from 30 to 100% and 9 to 50%, respectively, have been reported in various series [5, 9].

The optimal management of penetrating duodenopancreatic lesions continues to be a matter of debate and controversy. Although discordant opinions were reported in the literature regarding pyloric exclusion [13, 14], this procedure and drainage of the pancreas are the mainstays of surgical treatment [15, 16].

The site of the duodenal injury is crucial for determining the surgical approach, aiming not only at reconstructing duodenal continuity but also at avoiding suture line dehiscence [4].

Laceration of the duodenal bulb or superior flexure of the duodenum can be safely treated with gastric resection and by closure of the duodenal stump. When the injury is just below the ampulla of Vater, however, resection of the damage may be difficult. Mucosal or serosal patches and a pedicled graft with a free vascular pedicle created from stomach, jejunum or ileum tissue have been

previously proposed without proven efficacy [5, 17, 18, 19]. Duodenal drainage with a decompression tube, gastrojejunostomy, feeding jejunostomy, gastric resection with external duodenal drainage with Foley or Petzer tubes have also been recommended with conflicting reports of efficacy [20, 21, 22, 23].

In the presence of a duodenal lesion ranging from 50 to 70% of the circumference, Roux-en-Y duodenojejunostomy and duodeno-pancreatectomy procedures have also been proposed [23, 24], but with increased risk of dehiscence in cases of sepsis and peritonitis.

However, duodenal resection should be carried out when duodenal continuity or vascularization is interrupted; two procedures are currently being used. Resection of the duodenum with a primary end-to-end anastomosis should be performed in case of injury to the first, third and fourth segments. On the other hand, a pancreaticoduodenectomy should be reserved for selected cases of ampullary or proximal pancreatic duct injuries, massive peripancreatic hemorrhage and severe lesions of the duodenum and head of the pancreas [5, 25].

Therefore, when the pancreas is simultaneously involved in the gunshot damage, management is even more complex. Surgical management depends on the degree and location of the parenchymal lesion as well as on the presumed or evident integrity of the pancreatic duct [9]. Indeed, Bradley *et al.* [26] showed a significant association between injury to the main pancreatic duct and pancreas-related morbidity; furthermore, the overall morbidity is increased by delayed diagnosis and intervention [26, 27].

Surgical procedures, such as duodeno-pancreatectomy, segmental or total pancreatectomy, show high morbidity and mortality, especially in emergency setting and in the presence of multiple traumas [28]. Moreover, radical procedures may be contraindicated for the hemodynamic and metabolic conditions of these patients, often suffering from physiological pathologies such as dilutional coagulopathy, hypothermia and acidosis, the so called "killer triad" [29, 30].

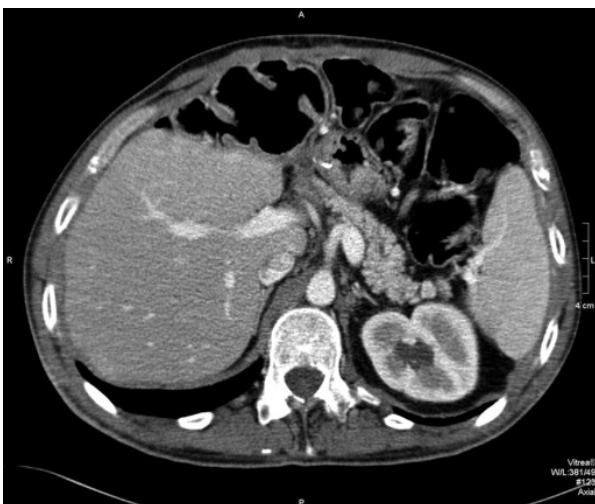


Figure 10. A final CT scan with post-processing multi-planar reconstruction was helpful in confirming complete resolution of the fluid collection after catheter removal.

The current opinion is that the appropriate treatment of the pancreatic trauma should be performed according to the type of injury (Table 1). Grade I and grade II injuries should be managed by hemostasis, debridement of devitalised tissue and adequate external drainage [9, 31]. The temptation to repair capsular laceration should be avoided because this may result in pseudocyst formation [9]. Grade III injuries require a distal pancreatectomy with closed suction drainage [9]. Grade IV and V injuries are frequently associated with multiple life-threatening traumas and generally require a damage-control approach with packing and wide external drainage [9].

Grade II pancreatic injury management associated with a Billroth II procedure and a jejunal resection was performed in the first operation in the case reported, but the appearance of a duodenal perforation due to severe posttraumatic necrotizing pancreatitis required an emergency re-laparotomy.

Indeed, in pancreaticoduodenal trauma, the need for re-laparotomy due to postoperative complications is frequently reported in the literature, accounting for an average of 2-5 operations for the patients [5, 11, 32].

The main postoperative complications requiring re-operation are duodenal and pancreatic related. The major duodenum-related complications are duodenal fistula and duodenal obstruction, ranging from 0 to 17% and from 1 to 1.8%, respectively [5, 33]. The pancreatic-related complications consist of pancreatic fistula (20-26%), intra-abdominal abscess (9-17%) and pseudocyst formation (5-15%) [34, 35, 36, 37], but pancreatitis is the prevailing postoperative complication, occurring in 30-72% of cases and

representing the main reason for mortality in pancreatic trauma [12, 38, 39].

Acute necrotizing pancreatitis is an objective diagnosis following contrast-enhanced CT which determines the extent of the necrosis and fluid collection, serially monitoring the progress; the diagnosis of the evolution of pancreatic necrosis into infection follows a positive culture or a CT scan showing gas pockets in and around the lesion.

Open pancreatic necrosectomy remains an important treatment for managing necrotizing pancreatitis, but mortality after debridement continues to be inordinately high [40, 41]. Mortality rates ranging from 20 to 70% have actually been reported in the literature, with sepsis and multiorgan failure as the most frequent causes [42, 43, 44, 45]. Moreover, a higher mortality rate was observed in patients with an increased APACHE II score, early persistent SIRS and unresolved multiorgan dysfunction [41].

In this report, the management complexity increased due to the accidental peripancreatic drain removal which forced further intervention.

Although recently minimally invasive necrosectomy techniques have been tried with satisfying results [46, 47, 48], they frequently necessitate multiple sessions for a definitive toilette [43] and have not been feasible in previous abdominal surgery for traumas. However, in the last decade, percutaneous CT-guided catheter drainage has been included in the management of necrotizing pancreatitis, even if the existing literature is limited [7, 42, 49].

Ultrasound or CT-guided drainage placement is reportedly effective in up to 90% of cases for drainage of acute fluid collections,

Table 1. Pancreatic organ injury scale: American Association for the Surgery of Trauma.

Grade*	Injury description
I	Minor contusion or superficial laceration without duct injury
II	Major contusion or laceration without duct injury or tissue loss
III	Distal transaction or parenchymal injury with duct injury
IV	Proximal (right of superior mesenteric artery) transaction or parenchymal injury
V	Massive disruption of pancreatic head

* Advance 1 grade when multiple injuries are present in the same organ.

pseudocysts or abscesses with a purely liquid content [42, 50]. Nevertheless, success rates for the drainage of contained fluid collection in necrotizing pancreatitis ranges from 26 to 50% because the infected collections are often not completely liquid and the possibility of removing the solid debris therein contained is equivocal [42, 49, 51]. The use of large bore catheters and the placement of several drainages has not yet been demonstrated definitively, and a prospective study seems to be necessary in order to evaluate the impact of drainage characteristics [42, 52].

However, percutaneous drainage allows a significant temporizing effect, especially in critically ill patients, postponing surgical intervention and leading to full recovery in several cases [49, 53, 54].

In conclusion, the treatment is successful when it is tailored to the clinical needs of the patient, especially if there are severe concomitant injuries or a prolonged course of treatment. As in the case reported, percutaneous drainage with targeted antibiotic therapy, based on bacterial cultures from FNA, should also be considered in all critically ill patients with post-traumatic necrotizing pancreatitis in order to avoid further hazardous surgical revision burdened by a high morbidity and mortality rates [42, 43, 44, 45]. Efforts to reduce mortality among patients with multiple pancreaticoduodenal penetrating gunshot traumas should focus on multidisciplinary surgical and minimally invasive treatment to optimize organ recovery.

Received April 24th, 2008 - Accepted May 13th, 2008

Keywords Abdominal Injuries; Drainage; Firearms; Pancreatitis, Acute Necrotizing; Wounds and Injuries

Conflict of interest The authors have no potential conflicts of interest

Correspondence

Mario Testini

Unit of Endocrine and General Surgery
Section of General and Thoracic Surgery

Department of Applications in Surgery of
Innovative Technologies
University Medical School of Bari
Policlinico, Piazza G Cesare
70124 Bari
Italy
Phone: +39-80.559.2882
Fax: +39-80.559.2882
E-mail: mario.testini@chirgen2.uniba.it

Document URL: <http://www.joplink.net/prev/200809/08.html>

References

1. Figl M, Weninger P, Hertz H. Gunshot Injuries - Incidence and Treatment. *Zentralbl Chir* 2007; 132:365-71. [PMID 17724642]
2. Witkowski Z, Lasek J, Kopiszka K, Stasiak M. Shotgun injuries--epidemiological and clinical aspects. *Wiad Lek* 2006; 59:341-5. [PMID 17017479]
3. Vasquez JC, Coimbra R, Hoyt DB, Fortlage D. Management of penetrating pancreatic trauma: an 11-year experience of a level-1 trauma center. *Injury* 2001; 32:753-9. [PMID 11754881]
4. Testini M, Piccinni G, Lissidini G, Di Venere B, Gurrado A, Poli E, et al. Management of Descending Duodenal Injuries Secondary to Laparoscopic Cholecystectomy. *Dig Surg* 2008; 25:12-15. [PMID 18235191]
5. Talving P, Nicol AJ, Navsaria PH. Civilian duodenal gunshot wounds: surgical management made simpler. *World J Surg* 2006; 30:488-94. [PMID 16547621]
6. Asensio JA, Stewart BM, Demetriades D. Duodenum. In: Ivatury RR, Cayten CG (editors). *The Textbook of Penetrating trauma*. Baltimore, Williams & Wilkins, 1996, p. 160.
7. Segal D, Morteale KJ, Banks PA, Silverman SG. Acute necrotizing pancreatitis: role of CT-guided percutaneous catheter drainage. *Abdom Imaging* 2007; 32:351-61. [PMID 17502982]
8. Lee JK, Kwak KK, Park JK, Yoon WJ, Lee SH, Ryu JK, et al. The efficacy of nonsurgical treatment of infected pancreatic necrosis. *Pancreas* 2007; 34:399-404. [PMID 17446837]
9. Al-Ahmadi K, Ahmed N. Outcomes after pancreatic trauma: experience at a single institution. *Can J Surg* 2008; 51:118-24. [PMID 18377752]
10. Kao LS, Bulger EM, Parks DL, Byrd GF, Jurkovich GJ. Predictors of morbidity after traumatic pancreatic injury. *J Trauma* 2003; 55:898-905. [PMID 14608163]
11. Lopez PP, Benjamin R, Cockburn M, Amortegui JD, Schulman CI, Soffer D, et al. Recent trends in the

management of combined pancreatoduodenal injuries. *Am Surg* 2005; 71:847-52. [PMID 16468533]

12. Ivanov PA, Grishin AV, Korneev DA, Ziniakov SA. Injuries of Pancreaticoduodenal organs. *Khirurgiia (Mosk)* 2003; 12:39-43. [PMID 14671603]

13. Velmahos GC, Constantinou C, Kasotakis G. Safety of repair for severe duodenal injuries. *World J Surg* 2008; 32:7-12. [PMID 17952703]

14. Seamon MJ, Pieri PG, Fisher CA, Gaughan J, Santora TA, Pathak AS, et al. A ten-year retrospective review: does pyloric exclusion improve clinical outcome after penetrating duodenal and combined pancreatoduodenal injuries? *J Trauma* 2007; 62:829-33. [PMID 17426536]

15. Mansour MA, Moore JB, Moore EE, Moore FA. Conservative management of combined pancreatoduodenal injuries. *Am J Surg* 1989; 158:531-5. [PMID 2589583]

16. Hwang SY, Choi YC. Prognostic determinants in patients with traumatic pancreatic injuries. *J Korean Med Sci* 2008; 23:126-30. [PMID 18303212]

17. De Shazo CV, Snyder WH, Daugherty CG, Crenshaw CA. Mucosal pedicle graft or jejunum for large gastrointestinal defects. *Am J Surg* 1972; 124:671-672. [PMID 5079805]

18. Papachristou DN, Fortner JG. Reconstruction of duodenal wall defects with the use of a gastric "island" flap. *Arch Surg* 1977; 112:199-200. [PMID 851478]

19. Walley BD, Goco I. Duodenal patch grafting. *Am J Surg* 1980; 140:706-708. [PMID 7435834]

20. Jones SA, Gazzaniga AB, Keller TB. The serosal patch: a surgical parachute. *Am J Surg* 1973; 126:186-196. [PMID 4721542]

21. Snyder WH 3rd, Weigelt JA, Watkins WL, Bietz DS. The surgical management of duodenal trauma. Precepts based on a review of 247 cases. *Arch Surg* 1980; 115:422-9. [PMID 7362449]

22. Ivatury RR, Gaudino J, Ascher E, Nallathambi M, Ramirez-Schon G, Stahl WM. Treatment of penetrating duodenal injuries: primary repair vs. repair with decompressive enterostomy/serosal patch. *J Trauma* 1985; 25:337-341. [PMID 4046085]

23. Carrillo EH, Richardson DJ, Miller FB. Evolution in the management of duodenal injuries. *J Trauma* 1996; 40:1037-45. [PMID 8656463]

24. Cogbill TH, Moore EE, Feliciano DV, Hoyt DB, Jurkovich GJ, Morris JA, et al. Conservative management of duodenal trauma: a multicenter perspective. *J Trauma* 1990; 30:1469-75. [PMID 2258957]

25. Ivatury RR. Duodenal injuries: small but lethal lesions. *Cir Gen* 2003; 25:59-64.

26. Bradley EL III, Young PR Jr, Chang MC, Allen JE, Baker CC, Meredith W, et al. Diagnosis and initial management of blunt pancreatic trauma: guidelines from a multiinstitutional review. *Ann Sur* 1998; 227:861-9. [PMID 9637549]

27. Oniscu GC, Parks RW, Garden OJ. Classification of liver and pancreatic trauma. *HPB (Oxford)* 2006; 8:4-9. [PMID 18333232]

28. Aldemir M, Taçyildiz I, Girgin S. Predicting factors for mortality in the penetrating abdominal trauma. *Acta Chir Belg* 2004; 104:429-434. [PMID 15469156]

29. Rotondo MF, Schwab CW, McGonigal MD, Phillips GR 3rd, Fruchterman TM, Kauder DR, et al. 'Damage control': an approach for improved survival in exsanguinating penetrating abdominal injury. *J Trauma* 1993; 35:375-82. [PMID 8371295]

30. Stawicki SP, Brooks A, Bilski T, Scaff D, Gupta R, Schwab CW, Gracias VH. The concept of damage control: Extending the paradigm to emergency general surgery. *Injury* 2008; 39:93-101. [PMID 17888435]

31. Boffard KD, Brooks AJ. Pancreatic trauma: injury to the pancreas and pancreatic duct. *Eur J Surg* 2000; 166:4-12. [PMID 10688209]

32. Rickard MJ, Brohi K, Bautz PC. Pancreatic and duodenal injuries: keep it simple. *Anz J Surg* 2005; 75:581-6. [PMID 15972052]

33. Asensio JA, Feliciano DV, Britt LD, Kerstein MD. Management of duodenal injuries. *Curr Probl Surg* 1993; 11:1023-93. [PMID 8222749]

34. Mayer JM, Tomczak R, Rau B, Gebhard F, Beger HG. Pancreatic injury in severe trauma: early diagnosis and therapy improve the outcome. *Dig Surg* 2002; 19:291-7. [PMID 12207073]

35. el-Boghdadly S, al-Yousef Z, al-Bedah K. Pancreatic injury: an audit and a practical approach. *Ann R Coll Surg Engl* 2000; 82:258-62. [PMID 10932660]

36. Feliciano DV, Martin TD, Cruse PA, Graham JM, Burch JM, Mattox KL, et al. Management of combined pancreatoduodenal injuries. *Ann Surg* 1987; 205:673-80. [PMID 3592810]

37. Cerwenka H, Bacher H, El-Shabrawi A, Kornprat P, Lemmerer M, Portugaller HR, Mischinger HJ. Management of pancreatic trauma and its consequences-guidelines or individual therapy? *Hepatogastroenterology* 2007; 54:581-4. [PMID 17523326]

38. Eramishantsev AK, Molitvoslovov AB, Filin AV. Traumatic injuries of the pancreas. *Khirurgiia (Mosk)* 1994; 4:13-7. [PMID 8041063]

39. Faroudy M, Mosadik A, Mouelhi S, Ababou A, Lazreq C, Sbihi A. The post-traumatic pancreatitis:

about four cases. *Ann Fr Anesth Reanim* 2006; 25:652-6. [PMID 16546346]

40. Rodriguez JR, Razo AO, Targarona J, Thayer SP, Rattner DW, Warshaw AL, et al. Debridement and closed packing for sterile or infected necrotizing pancreatitis: insights into indications and outcomes in 167 patients. *Ann Surg* 2008; 247:294-9. [PMID 18216536]

41. Mofidi R, Lee AC, Madhavan KK, Garden OJ, Parks RW. Prognostic factors in patients undergoing surgery for severe necrotizing pancreatitis. *World J Surg* 2007; 31:2002-7. [PMID 17687599]

42. Bruennler T, Langgartner J, Lang S, Wrede CE, Klebl F, Zierhut S, et al. Outcome of patients with acute, necrotizing pancreatitis requiring drainage-does drainage size matter? *World J gastroenterol* 2008; 14:725-30. [PMID 18205262]

43. Connor S, Ghaneh P, Raraty M, Rosso E, Hartley MN, Garvey C, et al. Increasing age and APACHE II score are the main determinants of outcome from pancreatic necrosectomy. *Br J Surg* 2003; 90:1542-8. [PMID 14648734]

44. Beger HG, Rau B, Isenmann R. Natural history of necrotizing pancreatitis. *Pancreatol* 2003; 3:93-101. [PMID 12774801]

45. Banks PA, Freeman ML. Practice Parameters Committee of the American College of Gastroenterology. Practice guidelines in acute pancreatitis. *Am J Gastroenterol* 2006; 101:2379-400. [PMID 17032204]

46. Bucher P, Pugin F, Morel P. Minimally invasive necrosectomy for infected necrotizing pancreatitis. *Pancreas* 2008; 36:113-9. [PMID 18376300]

47. Castellanos G, Piñero A, Serrano A, Llamas C, Fuster M, Fernandez JA, Parrilla P. Translumbar retroperitoneal endoscopy: an alternative in the follow-

up and management of drained infected pancreatic necrosis. *Arch Surg* 2005; 140:952-5. [PMID 16230544]

48. Carter R. Management of infected necrosis secondary to acute pancreatitis: a balanced role for minimal access techniques. *Pancreatol* 2003; 3:133-8. PMID 12774803]

49. Freeny PC, Hauptmann E, Althaus SJ, Traverso LW, Sinanan M. Percutaneous CT-guided drainage of infected acute necrotizing pancreatitis: techniques and results. *AJR Am J Roentgenol* 1998; 170:969-75. [PMID 9530046]

50. van Sonenberg E, Wittich GR, Goodacre BW, Casola G, D'Agostino HB. Percutaneous abscess drainage: update. *World J Surg* 2001; 25:362-9. [PMID 11343195]

51. Szentkereszty Z, Kerekes L, Hallay J, Czako D, Sápy P. CT-guided percutaneous peripancreatic drainage: a possible therapy in acute necrotizing pancreatitis. *Hepatogastroenterology* 2002; 49:1696-8. [PMID 12397769]

52. Szentkereszty Z, Sapy P. The role of percutaneous external drainage in the treatment of fluid collections associated with severe acute pancreatitis. What, when and how to drain? *Orv Hetil* 2007; 148:1395-9. [PMID 17631476]

53. Cheung MT, Ho CN, Siu KW, Kwork PC. Percutaneous drainage and necrosectomy in the management of pancreatic necrosis. *Anz J Surg* 2005; 75:204-7. [PMID 15839965]

54. Echenique AM, Sleeman D, Yrizarry J, Scagnelli T, Guerra JJ Jr, Casillas VJ, et al. Percutaneous catheter-directed débridement of infected pancreatic necrosis: results in 20 patients. *J Vasc Interv Radiol* 1998; 9:565-71. [PMID 9684824]