

## CASE REPORT

---

# Long-Term Survival in Metastatic Pancreatic Cancer. A Case Report and Review of the Literature

Gian Paolo Spinelli<sup>1</sup>, Angelo Zullo<sup>2</sup>, Adriana Romiti<sup>1</sup>, Marisa Di Seri<sup>1</sup>, Federica Tomao<sup>1</sup>,  
Evelina Miele<sup>1</sup>, Bruno Spalletta<sup>1</sup>, Annarita Eramo<sup>2</sup>, Cesare Hassan<sup>2</sup>, Silverio Tomao<sup>3</sup>

<sup>1</sup>Department of Experimental Medicine and Pathology, 'La Sapienza' University;

<sup>2</sup>Gastroenterology and Digestive Endoscopy, 'Nuovo Regina Margherita' Hospital; <sup>3</sup>'Regina Elena'  
National Cancer Institute. Rome, Italy

### ABSTRACT

**Context** Pancreatic cancer still remains an incurable disease. The survival rate of patients in all stages of the disease is poor. Overall median survival is 3-5 months with a 12-month survival rate of 10% and a 5-year survival rate less than 5%.

**Case report** We report a rare case of a long-term survivor (more than 10 years) of metastatic carcinoma of the pancreas tail controlled with subsequent surgical and chemotherapeutic strategies with an acceptable performance status and quality of life.

**Discussion** This is the fifth case reported in the literature showing that long-term survival may be achieved even in advanced pancreatic cancer.

---

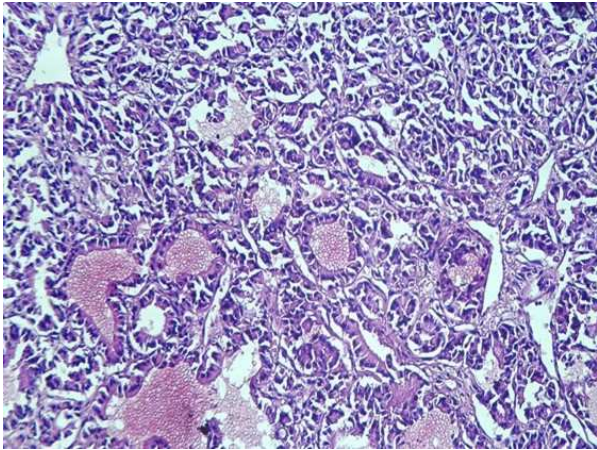
### INTRODUCTION

Pancreatic cancer remains one of the most severe neoplastic diseases since it is rarely detected in an early stage [1]. Although a small number of patients may be encountered in clinical practice some years after surgical resection integrated with other therapies, long-term survivors are actually uncommon.

Indeed, in the past decades, the prognosis of pancreatic cancer - mainly correlated with tumor stage - has not been significantly improved by any procedure [2]. The pattern of growth of pancreatic cancer is characterized by early spread to local tissues, lymphatic and perineural invasion, venous infiltration, and peritoneal metastases. Free cancer cells in the peritoneal cavity have been observed in 20-40% of cases, even in patients without nodal involvement who undergo early resection [2]. After surgical resection, the prognosis is affected by cancer dissemination and tumor cell differentiation. Patients with lymph-node metastases, perivascular and vessel invasion have a poor prognosis, even following an apparent complete resection. For such reasons, both locally advanced and metastatic pancreatic cancers remain a very difficult challenge for surgeons and oncologists. The investigation of new integrated approaches and new drugs for such a dreadful disease should always be encouraged [3].

### CASE REPORT

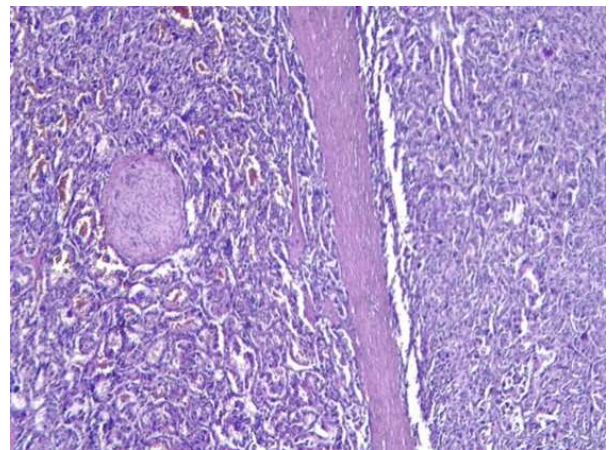
A 47-year-old man presented with severe upper abdominal pain in June 1995. An echotomography and CT were carried out showing a rounded expansive retroperitoneal mass, with a central hypodense area and



**Figure 1.** Cells with hyperchromatic and pleomorphic nuclei which define irregular glands.

without well-differentiated margins, localized in the uncinate process of the pancreas. Moreover, multiple hepatic lesions evocative of metastatic localizations were detected. The lesion together with the adjacent intestinal loop was resected in December 1995. A rounded yellowish neof ormation with a maximum diameter of 5.5 cm was removed, together with a 14 cm contiguous digiunal loop, and the peridigiunal fat tissue surrounding the neoplasia. Histological examination revealed a poorly differentiated adenocarcinoma of the pancreatic tail (Figures 1 and 2) with metastatic lesions in the pancreatic nodes and liver metastases at biopsy (pT1b pN1 pM1; stage III and histopathological grading G3). Starting in January 1996, chemotherapeutic treatment with a FEM schedule (5-FU: 600 mg/m<sup>2</sup> at days 1, 8, 29, 36; epirubicin: 30 mg/m<sup>2</sup> at days 1 and 29; mitomycin: 10 mg/m<sup>2</sup> at day 1) was given for 6 cycles. The CT restaging showed multiple liver lesions, the biggest measuring 6 cm in diameter. Thus, a second chemotherapeutic treatment with weekly gemcitabine (1,000 mg/m<sup>2</sup>) was given from December 1996 for 6 cycles. Stability was obtained and a monochemotherapeutic regimen with gemcitabine was performed. In October 2001 a CT revealed invasion of both the portal vein and the intrahepatic portal vessels. Chemotherapy using the De Gramont schedule (5-FU: 400 mg/m<sup>2</sup> i.v. bolus at days 1 and 2; 5-FU: 600 mg/m<sup>2</sup> i.v. at days 1, 2 by 22-h infusion; folinic acid: 200 mg/m<sup>2</sup> i.v. at

days 1 and 2 by 2-h infusion) was administered. In May 2002, following 6 cycles of this treatment, a CT control revealed a voluminous conglomerated mass of about 20 cm in diameter in the liver with involvement of hilar nodes. An OctreoScan scintigraphy of the liver showed a captation of the somatostatin-like tracer by the metastatic lesions and, therefore, lanreotide treatment was started. In July 2003, ascites were repeatedly drained, and the cytological assessment failed to find neoplastic cells. Therefore, the ascites were attributed to the portal hypertension caused by the tumoral obstruction of the portal vein system. A new chemotherapeutic approach with a GEMOX schedule (oxaliplatin 100 mg/m<sup>2</sup> at day 1; gemcitabine 1,500 mg/m<sup>2</sup> at days 1 and 8) every 3 weeks for 12 cycles was carried out. The treatment was given until July 2004 with acceptable tolerance and toxicity and a good control of the disease. The patient was supported with weekly administration of darbopietin alpha for G2 anemia and repeated infusions of albumin. In September 2004 a restaging with total body CT showed lung progression disease and peritoneal carcinosis. Starting in October 2004, treatment with 5-fluorouracil 200 mg/m<sup>2</sup> (from day 1 to 7 by continuous infusion) concomitant with hyperthermia was started, but the treatment was stopped after a few applications due to elevated toxicity. Some episodes of hematemesis were successfully controlled by endoscopic treatment. To date,



**Figure 2.** Perineural invasion.

**Table 1.** Randomized trials for metastatic pancreatic cancer containing 5-fluorouracil (5-FU).

Trial	Dose/schedule	No. of patients	Response rate	Median survival time (months)
Crown <i>et al.</i> [30]	5-FU 370 mg/m <sup>2</sup> x 5 days plus leucovorin 500 mg/m <sup>2</sup> (every 4 weeks)	20	0%	2.5 (range: 0.5-25)
Bruckner <i>et al.</i> [31]	5-FU 30 mg/m <sup>2</sup> plus leucovorin 100-200 mg/m <sup>2</sup> (every 2 weeks)	8	50%	NA
DeCaprio <i>et al.</i> [32]	5-FU 600 mg/m <sup>2</sup> , plus leucovorin 500 mg/m <sup>2</sup> (weekly)	27	7 %	6.2 (range: 0.2-33)
Palmer <i>et al.</i> [33]	5-FU plus adriamycin plus mitomycin	43	NA	8 vs. 4 in the untreated group
Glimelius <i>et al.</i> [34]	5-FU and leucovorin plus etoposide	90	36%	6.0 vs. 2.5 for basic supportive care
Louvet <i>et al.</i> [35]	Leucovorin 200 mg/m <sup>2</sup> by 2-h infusion, plus 5-FU 400 mg/m <sup>2</sup> bolus, plus 5-FU 600 mg/m <sup>2</sup> by 22-h infusion (days 1 and 2; every 3 weeks)	20	10%	6 (4 patients alive after 1 year)

NA: not available

10.5 years after the diagnosis, the patient is in an acceptable general condition without any oncological therapy.

## DISCUSSION

Treatment of metastatic pancreatic cancer still remains a challenge and the median survival time of locally advanced or metastatic disease is very poor (3-6 months) [4], the 5-year survival rate being only 3-4.2%, even in patients who underwent resection [1, 4]. Due to such a dismal prognosis, it is very difficult to conceive guidelines for a multidisciplinary treatment of the disease. For a long time, only 5-fluorouracil (5-FU) [5] has been used, having shown an acceptable response rate (20%) and low toxicity in pancreatic cancer [6, 7], also supported by colorectal and gastric cancer studies. The increasing interest in this drug has led to its larger use in randomized studies, searching schedules or modulators improving its activity and reducing its toxicity. The results have shown that the combination of 5-FU with other drugs such as doxorubicin (FA), cisplatin or the association of doxorubicin plus mitomycin (FAM), are

not advantageous in terms of time to progression, objective response rate and median survival time [8, 9, 10, 11, 12, 13, 14], with increased toxicity as compared to the use of 5-FU alone (Table 1). Survival improvement and clinical benefits found in a phase III trial [15], including palliation of symptoms and disease regression, suggest the use of gemcitabine as a standard therapy for patients with advanced pancreatic cancer. However, only 25% of patients had significant clinical benefits, with tumor regression in only 5% of the cases [16]. The need for new approaches has led to several trials to test the combination of gemcitabine with other cytotoxic agents. In the phase II study carried-out by Alberts *et al.* [16], the efficacy of gemcitabine and oxaliplatin was analyzed, showing moderate activity in patients with advanced pancreatic cancer. Other studies [5, 17] have confirmed that this combination provides a better response rate and progression free survival with a limited toxicity than gemcitabine alone (Table 2). Despite the low median survival time of resected and plurtreated patients, a small subset of long-term survivors does exist. Very



few cases of patients with advanced pancreatic cancer surviving for more than 5 years have been described [18, 19, 20], and an 8% 7-year survival for patients with surgically resected cancer has been reported [21]. To date, only four patients living more than 10 years have been described in the literature [22, 23]. Interestingly, all these very long-term survivors were Japanese and all had resectable disease. Some negative prognostic factors of survival have been suggested, including tumor size (greater than 2 cm), positive nodes, poor histological differentiation, vessels and capsule invasion, and positive pathologic margins [24, 25]. Others considered invasion of both retroperitoneal tissues and the portal venous system as the main negative predictors for a post-operative prognosis [24, 26]. It has also been found that patients with initial jaundice have a significantly better prognosis than other patients [27]. In addition, long-term survivors were more frequently female [1]. Surprisingly, despite the fact that several of these negative predictive factors (tumor size, positive nodes, poor differentiation, portal invasion, no jaundice, male sex) were present, long-term survival has been observed in our patient.

Unfortunately, we only know unfavorable prognostic factors whereas there is a lack of information on clinical or biological parameters predictive of a better outcome.

Recent studies suggest that interferon gamma polymorphism seems to be correlated with the duration of survival in pancreatic cancer, the presence of allele 2 (12 CA-repeat sequences) being associated with long survival in non-resectable pancreatic cancer [28]. Therefore, such assessment may be useful in the near future as a positive prognostic predictor. Moreover, a complex network of chemokines and receptors exists in the tumor micro-environment, regulating a variety of functions such as angiogenesis, activation of matrix metalloproteases, growth-promoting effects and inhibition of apoptosis. In particular, the expression of CXCR4 on metastatic pancreatic carcinoma cells promotes tumor cell migration, matrix degradation and invasion, proliferation and survival, opening new ways for valuable therapeutic targets [29]. Indeed, immunotherapy and anti-angiogenesis therapy might be a hopeful strategy in the near future, as has emerged in animal models [3].

In conclusion, this is the fifth case reported in the literature showing that long-term survival may be achieved even in advanced pancreatic cancer. Moreover, this is the first patient with inoperable metastases at the time of diagnosis who has survived for more than 10 years.

---

Received June 8<sup>th</sup>, 2006 - Accepted July 18<sup>th</sup>, 2006

**Table 2.** Trials for metastatic pancreatic cancer containing gemcitabine and oxaliplatin combination.

Trial	Study drug	Dose (mg/m <sup>2</sup> )	Days	Weeks	No. of patients	Response rate	Median survival time (months)
Alberts <i>et al.</i> [36]	Gemcitabine oxaliplatin	1,000 100	1 and 8 1	Every 3 weeks Every 3 weeks	46	30%	8.7
Louvet <i>et al.</i> [37]	Gemcitabine oxaliplatin	1,000 100	1 x 2	Every 2 weeks Every 2 weeks	32	31%	62% patients alive at 6 months
Garnier <i>et al.</i> [38]	Gemcitabine oxaliplatin 5-FU bolus 5-FU infusion leucovorin	800 100 400 1,000 200	x 3 1 1 1 and 2 1	Every 3 weeks Every 3 weeks Every 3 weeks Every 3 weeks Every 3 weeks	30	29%	8
Louvet <i>et al.</i> [17]	Gemcitabine oxaliplatin	1,000 100	1 2	Every 2 weeks Every 2 weeks	313	26.8%	9
Demols <i>et al.</i> [39]	Gemcitabine oxaliplatin	1,000 100	1 2	Every 2 weeks Every 2 weeks	33	61.2%	6 (range: 0.5-21)

**Keywords** Chemotherapy, Adjuvant; Drug Therapy; Pancreatic Neoplasms; Survivors

### Correspondence

Silverio Tomao  
'Regina Elena' National Cancer Institute  
Via E. Chianesi, 53  
00100 Roma  
Italy  
Phone: +39-06.5266.5929  
Fax: +39-06.5266.5920  
E-mail: silverio.tomao@uniroma1.it

---

### References

1. Saif MW, Svegliani H, Carpenter M. Impact of ethnicity on outcome in pancreatic carcinoma. *JOP. J Pancreas (Online)* 2005; 6:246-54. [PMID 15883478]
2. Matsuno S, Egawa S, Arai K. Trends in treatment for pancreatic cancer. *J Hepatobiliary Pancreat Surg* 2001; 8:544-8. [PMID 11956906]
3. Matsumoto G, Nagai S, Muta M, Tsuruta K, Okamoto A, Toi M. Survival benefit of KRN7000 immune therapy in combination with TNP470 in hamster liver metastasis model of pancreatic cancer. *Oncol Rep* 2003; 10:1201-6. [PMID 12883681]
4. el-Kamar FG, Grossbard ML, Kozuch PS. Metastatic pancreatic cancer: emerging strategies in chemotherapy and palliative care. *Oncologist* 2003; 8:18-34. [PMID 12604729]
5. Pasetto LM, Jirillo A, Stefani M, Monfardini S. Old and new drugs in systemic therapy of pancreatic cancer. *Crit Rev Oncol Hematol* 2004; 49:135-51. [PMID 15012974]
6. O'Connell MJ. Current status of chemotherapy for advanced pancreatic and gastric cancer. *J Clin Oncol* 1985; 3:1032-9. [PMID 3894585]
7. Arbuck SG. Overview of chemotherapy for pancreatic cancer. *Int J Pancreatol* 1990; 7:209-22. [PMID 2081925]
8. Andre T, Lotz JP, Bouleuc C, Azzouzi K, Houry S, Hannoun L, et al. Phase II trial of 5-Fluorouracil, Leucovorin and cisplatin for treatment of advanced pancreatic adenocarcinoma. *Ann Oncol* 1996; 7:173-8. [PMID 8777174]
9. Rouger P, Ducreux M, Douillard J, Seitz JF, Bugat R, Bosses JF, et al. Efficacy of 5-FU + cisplatin compared to bolus 5-FU in advanced pancreatic carcinoma: a randomized trial from the French Anticancer Digestive Group. *Proc Am Soc Clin Oncol* 1999; 18:274a (Abstract 1114).
10. Cullinan SA, Moertel CG, Fleming TR, Rubin JR, Krook JE, Everson LK, et al. A comparison of three chemotherapeutic regimens in the treatment of advanced pancreatic and gastric carcinoma. Fluorouracil vs fluorouracil and doxorubicin vs fluorouracil, doxorubicin, and mitomycin. *JAMA* 1985; 253:2061-7. [PMID 2579257]
11. Phase II studies of drug combinations in advanced pancreatic carcinoma: fluorouracil plus doxorubicin plus mitomycin C and two regimens of streptozotocin plus mitomycin C plus fluorouracil. The Gastrointestinal Tumor Study Group. *J Clin Oncol* 1986; 4:1794-8. [PMID 2946815]
12. Kelsen D, Hudis C, Niedzwiecki D, Dougherty J, Casper E, Botet J, et al. A phase III comparison trial of streptozotocin, mitomycin, and 5-fluorouracil with cisplatin, cytosine arabinoside, and caffeine in patients with advanced pancreatic carcinoma. *Cancer* 1991; 68:965-9. [PMID 1833042]
13. Cullinan S, Moertel CG, Wieand HS, Schutt AJ, Krook JE, Foley JF, et al. A phase III trial on the therapy of advanced pancreatic carcinoma. Evaluations of the Mallinson regimen and combined 5-fluorouracil, doxorubicin, and cisplatin. *Cancer* 1990; 65:2207-12. [PMID 2189551]
14. Mallinson CN, Rake MO, Cocking JB, Fox CA, Cwynarski MT, Diffey BL, et al. Chemotherapy in pancreatic cancer: results of a controlled, prospective, randomised, multicentre trial. *Br Med J* 1980; 281:1589-91. [PMID 7004559]
15. Burris HA 3rd, Moore MJ, Andersen J, Green MR, Rothenberg ML, Modiano MR, et al. Improvements in survival and clinical benefit with gemcitabine as first-line therapy for patients with advanced pancreas cancer: a randomized trial. *J Clin Oncol* 1997; 15:2403-13. [PMID 9196156]
16. Alberts SR, Townley PM, Goldberg RM, Cha SS, Sargent DJ, Moore DF, et al. Gemcitabine and oxaliplatin for metastatic pancreatic adenocarcinoma: a North Central Cancer Treatment Group phase II study. *Ann Oncol* 2003; 14:580-5. [PMID 12649105]
17. Louvet C, Labianca R, Hammel P, Lledo G, Zampino MG, Andre T, et al. Gemcitabine in combination with oxaliplatin compared with gemcitabine alone in locally advanced or metastatic pancreatic cancer: results of a GERCOR and GISCAD phase III trial. *J Clin Oncol* 2005; 23:3509-16. [PMID 15908661]
18. Kurihara K, Nagai H, Kasahara K, Kawai T, Saito K, Kanazawa K. Pleomorphic carcinoma of the pancreas with massive lymphocytic stromal infiltration and long-term survival after resection. *Int J Pancreatol* 2000; 27:241-8. [PMID 10952407]
19. Toyooka S, Tsukuda K, Mizuta M, Soh J, Shirakawa K, Shimizu K, Shimizu N. A case of

pancreatic adenocarcinoma with novel K-ras mutation and long term survival. *Am J Gastroenterol* 2002; 97:1852-3. [PMID 12135058]

20. Shimada K, Kosuge T, Yamamoto J, Yamasaki S, Sakamoto M. Successful outcome after resection of pancreatic cancer with a solitary hepatic metastasis. *Hepatogastroenterology* 2004; 51:603-5. [PMID 15086214]

21. Yeo CJ, Sohn TA, Cameron JL, Hruban RH, Lillmoed KD, Pitt HA. Periampullary adenocarcinoma: Analysis of 5-year survivors. *Ann Surg* 1998; 227:821-31. [PMID 9637545]

22. Ozaki H, Kinoshita T, Kosuge T, Shimada K, Yamamoto J, Tokuye K, et al. Long-term survival after multimodality treatment for resectable pancreatic cancer. *Int J Pancreatol* 2000; 27:217-24. [PMID 10952404]

23. Yoshizawa K, Nagai H, Kurihara K, Sata N, Kawai T, Saito K. Long-term survival after surgical resection for pancreatic cancer. *Hepatogastroenterology* 2001; 48:1153-6. [PMID 11490822]

24. Tsuchiya R, Harada N, Tsunoda T, Miyamoto T, Ura K. Long-term survivors after operation on carcinoma of the pancreas. *Int J Pancreatol* 1988; 3:491-6. [PMID 3221109]

25. Geer RJ, Brennan MF. Prognostic indicators for survival after resection of pancreatic adenocarcinoma. *Am J Surg* 1993; 165:68-72. [PMID 8380315]

26. Nagakawa T, Sanada H, Inagaki M, Sugama J, Ueno K, Konishi I, et al. Long-term survivors after resection of carcinoma of the head of the pancreas: significance of histologically curative resection. *J Hepatobiliary Pancreat Surg* 2004; 11:402-8. [PMID 15619016]

27. Watanabe I, Sasaki S, Konishi M, Nakagohri T, Inoue K, Oda T, Kinoshita T. Onset symptoms and tumor locations as prognostic factors of pancreatic cancer. *Pancreas* 2004; 28:160-5. [PMID 15028948]

28. Halma MA, Wheelhouse NM, Barber MD, Powell JJ, Fearon KC, Ross JA. Interferon-gamma polymorphisms correlate with duration of survival in pancreatic cancer. *Hum Immunol* 2004; 65:1405-8. [PMID 15556691]

29. Marchesi F, Monti P, Leone BE, Zerbi A, Vecchi A, Piemonti L, et al. Increased survival, proliferation, and migration in metastatic human pancreatic tumor cells expressing functional CXCR4. *Cancer Res* 2004; 64:8420-7. [PMID 15548713]

30. Crown J, Casper ES, Botet J, Murray P, Kelsen DP. Lack of efficacy of high-dose leucovorin and

fluorouracil in patients with advanced pancreatic adenocarcinoma. *J Clin Oncol* 1991; 9:1682-6. [PMID 1875224]

31. Bruckner HW, Crown J, McKenna A, Hart R. Leucovorin and 5-fluorouracil as a treatment for disseminated cancer of the pancreas and unknown primary tumors. *Cancer Res* 1988; 48:5570-2. [PMID 3046742]

32. DeCaprio JA, Mayer RJ, Gonin R, Arbuck SG. Fluorouracil and high dose leucovorin in previously untreated patients with advanced adenocarcinoma of the pancreas: results of a phase II trial. *J Clin Oncol* 1991; 9:2128-33. [PMID 1960554]

33. Palmer KR, Kerr M, Knowles G, Cull A, Carter DC, Leonard RC. Chemotherapy prolongs survival in inoperable pancreatic carcinoma. *Br J Surg* 1994; 81:882-5. [PMID 8044610]

34. Glimelius B, Hoffman K, Sjoden PO, Jacobsson G, Sellstrom H, Enander LK, et al. Chemotherapy improves survival and quality of life in advanced pancreatic and biliary cancer. *Ann Oncol* 1996; 7:593-600. [PMID 8879373]

35. Louvet C, Beerblock K, de Gramont A, Varette C, Demuynck B, Bennamoun M, et al. High-dose folinic acid, 5-fluorouracil bolus and infusion in advanced pancreatic adenocarcinoma: a pilot study. *Eur J Cancer* 1993; 29A:1217. [PMID 8518038]

36. Alberts SR, Townley PM, Goldberg RM, Cha SS, Moore DF Jr, Krook JE, et al. Gemcitabine and oxaliplatin for patients with advanced or metastatic pancreatic cancer: a North Central Cancer Treatment Group (NCCTG) phase I study. *Ann Oncol* 2002; 13:553-7. [PMID 12056705]

37. Louvet C, Andre T, Lledo G, Hammel P, Bleiberg H, Bouleuc C, et al. Gemcitabine-oxaliplatin (GEMOX) combination in advanced pancreatic carcinoma (APC): a Gercor multicenter phase II study. *Proc Am Soc Clin Oncol* 2001; 20:Abstract 506.

38. Garnier C, Rebischung C, Chirpaz E, Balosso J, Fournet J, Pasquier D, et al. Phase II study of a combination with leucovorin (LV), 5 FU bolus and infusion (FU), gemcitabine (GEM) and oxaliplatin (LOHP) (FOLFU GEMOX regimen) in locally advanced (LA) and metastatic (M) pancreatic carcinoma (APC). *Proc Am Soc Clin Oncol* 2001; 20:Abstract 620.

39. Demols A, Peeters M, Polus M, Marechal R, Gay F, Monsaert E, et al. Gemcitabine and oxaliplatin (GEMOX) in gemcitabine refractory advanced pancreatic adenocarcinoma: a phase II study. *Br J Cancer* 2006; 94:481-5. [PMID 16434988]