

# Informed Surgical Consent - Expect the Unexpected: Discrepancies in Imaging and Its Implications on Consent with Focus On Recurrent Ipsilateral Ectopic Pregnancy after Previous Salpingectomy - A Case Report

**Tabassum S\*, Shah A and Agrawal D**

Department of Obstetrics and Gynaecology,  
Yeovil Hospital, United Kingdom

\*Corresponding author: Shumaila Tabassum

## Abstract

Most acute gynaecological admissions needing emergency surgery are either ectopic pregnancy or ovarian cysts. The ultrasound imaging plays a vital role in the diagnosis and surgical intervention is planned accordingly. It is not uncommon to confirm the side of pathology after a diagnostic laparoscopy and then continue to treat the affected side. A 38-year-old woman presented with abdominal pain 4 weeks after her last menstrual period. She had a left salpingectomy for tubal ectopic pregnancy about 8 years ago. Examination was suggestive of acute abdomen. Serum quantitative HCG was 3959  $\mu$ /l, significant drop in haemoglobin noted within 12 hours of admission. Transvaginal ultrasonography confirmed the absence of an intra-uterine pregnancy and presence of a complex mass in the right fallopian tube. She was consented for laparoscopy and right salpingectomy based on the radiological images. Prior to the surgery, the consent form was amended to 'laparoscopy and removal of the affected fallopian tube'. Laparoscopic evaluation revealed haemoperitoneum and ectopic pregnancy in left tubal stump. Haemoperitoneum was evacuated and the left stump was removed. The discrepancies and errors in radiological studies should always be born in mind when deciding surgical management of a patient and addressed in taking the informed consent.

**Keywords:** Informed surgical consent; Ultrasound; Recurrent ipsilateral ectopic pregnancy

**Abbreviations:** HCG: Human Chorionic Gonadotrophin; RBC: Red Blood Cells; CI: Confidence Interval; ISC: Informed Surgical Consent

✉ shumaila1910@gmail.com

Department of Obstetrics and Gynaecology,  
Yeovil Hospital, United Kingdom.

Tel: +44-7546989110

**Citation:** Tabassum S, Shah A, Agrawal D (2021) Informed Surgical Consent - Expect the Unexpected: Discrepancies in Imaging and Its Implications on Consent with Focus On Recurrent Ipsilateral Ectopic Pregnancy after Previous Salpingectomy - A Case Report. Gynecol Obstet Case Rep Vol.7 No.3:11

**Received:** February 19, 2021; **Accepted:** March 10, 2021; **Published:** March 17, 2021

## Introduction

Errors and discrepancies in radiology practice are surprisingly common, with an estimated day to day rate of 3-5% of studies reported [1]. Contrary to the physical examination of patients, or evaluation at surgery or endoscopy, evidence of a radiologic examination remains available for subsequent scrutiny and can be used to assess observer variation [2]. The discrepancies and errors in reporting of radiological studies should always be born in mind when deciding surgical management of a patient and addressed in taking the informed consent.

Traditional approach to the healthcare was based on the dictum of "trust me, I am a doctor" and involvement of patients in decision making and understanding the rationale behind the decision was never considered. The role of healthcare professional is to provide information on all the options available to the patient, discuss the risks and benefits associated with each option, and take patient's views and consent into account before any form of treatment can be started. Obtaining consent from the patient, which is the first step towards respecting patient's autonomy, primarily depends on the working diagnosis aided by investigations and imaging studies.

We report a case where a spontaneous recurrent ectopic pregnancy was found in the stump of the previously removed fallopian tube, with the radiological images suggestive of tubal mass on the opposite side.

## Case Presentation

A 38-year-old woman presented to the emergency department in her 11<sup>th</sup> pregnancy with severe abdominal pain along with shoulder tip pain 4 weeks after her last menstrual period. She had a laparoscopic left salpingectomy for left tubal ectopic pregnancy about 8 years ago. This was followed by a first trimester miscarriage, 2 spontaneous vaginal deliveries and a caesarean section. On physical examination, the patient was normotensive but tachycardic. Abdomen was soft with generalised tenderness and guarding. Serum quantitative HCG was 3959  $\mu$ /l. Haemoglobin was 103 g/l on admission and dropped down significantly to 82 g/l within 12 hours of admission. Transvaginal ultrasonography confirmed the absence of an intra-uterine pregnancy and presence of a complex mass in the right fallopian tube measuring 24 mm  $\times$  30 mm (**Figure 1**). Free fluid extending to the upper abdomen within the Morrison's pouch was also noted.

The junior doctor attending this patient consented her for laparoscopy and right salpingectomy based on the radiological images. Prior to the surgical procedure, the on-call consultant reviewed the patient and looking at the wider spectrum of the clinical picture, he amended the consent form to 'laparoscopy and removal of the affected fallopian tube' after having a discussion with the patient about the rationale behind this change in the consent.

Laparoscopic evaluation revealed 500 ml of haemoperitoneum and evidence of a prior left salpingectomy. Oozing of blood from left tubal stump was noted. The right tube looked normal. Haemoperitoneum was evacuated and the left stump was removed ensuring adequate haemostasis.

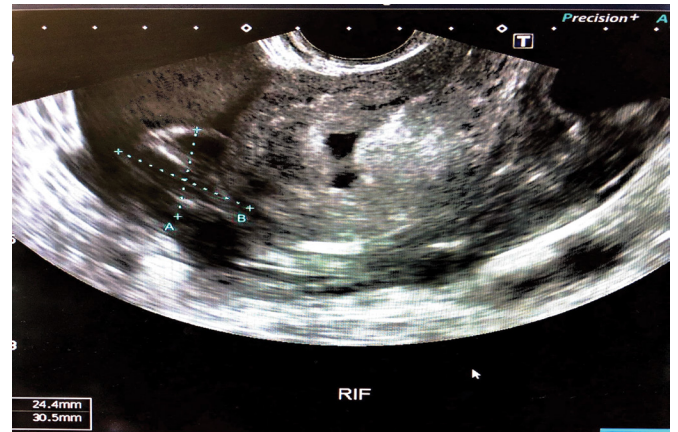
## Outcome and follow up

Patient was transfused 2 units of RBCs after the surgical procedure. She had an uneventful recovery in the post-operative period and was discharged on day 2. Serial quantitative HCG monitoring revealed a drop from 3959  $\mu$ /l pre- surgery to 608  $\mu$ /l and 52  $\mu$ /l on day-2 and day-7 post-operative respectively.

## Discussion

Ectopic pregnancy is defined as a pregnancy that implants outside the uterine cavity. Ectopic pregnancy affects approximately one in 80 pregnancies [3]. The incidence of recurrent ectopic pregnancy is approximately 10-27% [4]. The clinical presentation varies widely and the classic triad of amenorrhea, abdominal pain and vaginal bleeding is seen only in 50% of the patients.

Several risk factors for ectopic pregnancy have been suggested, with some of the commonly encountered being, a history of pelvic inflammatory disease (PID), smoking at the time of conception, prior ectopic pregnancy, previous pelvic surgery, induction of ovulation, and intrauterine device usage [5]. There



**Figure 1** Transvaginal ultrasound scan of the right adnexa, demonstrating a complex mass in the right fallopian tube.

has been no individual study conducted so far to evaluate the factors predisposing to the risk for recurrent ectopic pregnancy in tubal stump, but it has been found that ipsilateral salpingectomy is a risk factor unique to interstitial pregnancy. Gao et al. studied a total of 414 cases of interstitial pregnancy, of which 46 (11.1%) were after an ipsilateral salpingectomy [6]. Ipsilateral recurrent ectopic pregnancy after total salpingectomy is a rare occurrence and in theory should not happen. A number of theories have been postulated about the mechanisms involved in recurrent ipsilateral ectopic pregnancy [7].

In recent years, ultrasound has become an essential tool in the assessment of women with suspected early pregnancy complications. The initial sonographic criteria for the diagnosis of a tubal ectopic were published by Kobayashi Rajah et al. [8]. A complex adnexal mass, an empty uterus and a positive pregnancy test is mostly suggestive of an extra-uterine pregnancy and is by far the most common sonographic presentation. A large prospective study reported the sensitivity of the initial transvaginal ultrasound scan in the diagnosis of ectopic pregnancy as 73.9% (95% CI: 65.1-81.6), with a specificity of 99.9% (95% CI: 99.8-100), a positive predictive value of 96.7% (95% CI: 90.7-99.3), and a negative predictive value of 99.4% (95% CI: 99.2-99.6) [9].

Informed Surgical Consent (ISC) before an invasive procedure is an ethical obligation, and it is vital to involve the patient in decision-making regarding the treatment. This concept holds a legal angle as well. No one has the right to even touch, let alone treat another person, since any such act, if done without permission, is punishable. Well-informed patients are generally more satisfied and file fewer legal claims [10]. Informed Surgical Consent (ISC) serves a dual action, as it not only protects the patient rights, but also legally safeguards the surgical personnel. Surgeons are obliged to avoid any unnecessary interventions and unplanned surgical procedures [11].

The importance of consent is perhaps best illustrated by its ability to transform actions which would ordinarily constitute serious assault, into legal, voluntary occurrences, well as the

individual being protected from bodily invasion by the criminal law, the civil law takes a similarly dim view of treatment without consent, leaving those who fail to obtain proper consent open to litigation, where suit was filed under tort of battery on the basis that consent was not obtained due to lack of disclosure. It might, therefore, be seen as a matter of common sense that an individual must give their consent before their body is interfered with. However, this has not always been the case with regards to the practice of medicine, with tensions arising between the practitioners' views of what should be done and the patients' views of what they wish to be done.

When consent is obtained with limited information, inadequate communication and understanding, or when there are questions regarding the capacity to consent, it is not valid. In the past, the doctors would make the decision on the basis of best interest of the patient, but this disregarded the beliefs and values of the patient. Hence, the decisions were based on the best interest from medical point of view and not necessarily individualised for the patients, bypassing their autonomy to decide what is best for them.

An interesting case, which apparently was about medical negligence and causation, but started the debate about patient's autonomy. In this case, the patient was awarded damages according to the loss caused by injury, while the decision was based on loss of right to make an informed decision. This case initiated the shift from medical paternalism towards patient's autonomy. Lord Steyn clearly said:

*"In modern law, medical paternalism no longer rules and a patient has a prima facie right to be informed by a surgeon of a small, but well established, risk of serious injury as a result of surgery."*

The outcome of consent is dependent on many factors, particularly how the information was conveyed to the patient. However, the facts presented in a particular way can affect the decision making process. This is specifically true when a patient holds a profound trust in the medical professional to guide the patient in making the right choice. The concern raised by some authorities is that whether consent complements patient autonomy and protects the patient's right to choose, or it is replacing the autonomy where a healthcare professional obtains a signature on a piece of paper, and tries to satisfy himself that the patient's right to choose and free will has been protected.

The case discussed has revealed implications in situations like ovarian cysts, which are more commonly encountered in gynaecology setting than ectopic pregnancies. In case of large ovarian cysts, it is logical to find it difficult to identify the side to which they belong radiologically and hence, this scenario should be openly discussed with the patients while taking consent in order to comply with GMC standards and most importantly to avoid litigation in future.

In our case, had the consultant not amended the consent prior to surgery, it would have been a dilemma to find the ectopic

pregnancy on the side contrary to what radiological imaging suggested, keeping in view that carrying out a surgery for which patient has not been consented is absolutely unacceptable. Hence, our case reflects the importance of taking into consideration the broader picture of clinical presentation rather than relying solely on individual elements and nevertheless, this practice should form the basis of the discussion while involving the patients in shared decision-making.

## Conclusion

Although a salpingectomy does not necessarily eradicate all ipsilateral ectopics, it undoubtedly reduces the risk of a recurrent tubal ectopic on the same side. On the other hand, it is erroneous to believe that total salpingectomy is always as complete as the word implies. Such cases that leave a tubal residue warrant a high index of clinical suspicion. Errors are inevitable, in medicine as in life, and the concept of necessary fallibility must be accepted. Informed consent is an established ethical and legal requirement for surgical treatment. A valid consent requires more than a 'box-checking' exercise, and it is not the case that 'one size fits all'. Each case and scenario is different and unique, and deserves to be treated as such.

We conclude that, taking into view the importance of consent, it is advisable to discuss with all the patients, the possibility of contralateral side being affected and hence, the consent should include the management of affected side as seen at surgical procedure, and not specific side as reported on a radiological imaging.

## Contributors

- Shumaila Tabassum carried out the literature search, collected all the data published so far, and created the initial draft.
- Ahmar Shah was involved in patient's care as a lead clinician, contributed in editing portions of the initial draft and helped in completing the final manuscript.
- Divya Agrawal contributed in editing portions of the initial draft and helped in completing the final manuscript.
- All authors have approved the final version of the manuscript.

## Conflict of Interest

The authors declare that they have no conflict of interest regarding the publication of this case report.

## Funding

No funding from an external source supported the publication of this case report.

## Patient Consent

Patient consent is obtained.

## References

- 1 Waite S, Scott J, Gale B, Fuchs T, Kolla S, et al. (2017) Interpretive Error in Radiology. *America J Roentgenol* 208: 739-749.
- 2 Brady A, Laoide RÓ, McCarthy P, McDermott R (2012) Discrepancy and error in radiology: Concepts, causes and consequences. *Ulster Med J* 81: 3-9.
- 3 Elson CJ, Salim R, Potdar N, Chetty M, Ross JA, et al. (2016) On behalf of the royal college of obstetricians and gynaecologists: Diagnosis and management of ectopic pregnancy. *BJOG* 123: e15-e55.
- 4 Petrini A, Spandorfer S (2020) Recurrent ectopic pregnancy: Current Perspectives. *Int J Womens Health* 12: 597-600.
- 5 Sabira S, Asif MH, Akhtar N (2015) Incidence rate and prevalence of major risk in the Pakistani population: Mini-review factors for ectopic pregnancy. *Asian Pacific J Tropical Dis* 5: 246-250.
- 6 Gao MY, Zhu H, Zheng FY (2019) Interstitial pregnancy after ipsilateral salpingectomy: Analysis of 46 cases and a literature review. *J Minim Invasive Gynecol* 27: 613-617.
- 7 Boykin T (2016) Ipsilateral recurrent tubal ectopic pregnancy following a salpingectomy. *J Diagnostic Med Sonograph* 33: 114-119.
- 8 Rajah K, Goodhart V, Zamora KP, Amin T, Jauniaux E, et al. (2018) How to measure size of tubal ectopic pregnancy on ultrasound. *Ultrasound Obstet Gynecol* 52: 103-109.
- 9 Kirk E, Tan L, Mukri F, Bottomley C, Condous G, et al. (2007) OC58: Ectopic pregnancy diagnosis and management: A 4-year experience. *Ultrasound Obstet Gynecol* 30: 385.
- 10 Agozzino E, Borrelli S, Cancellieri M, Carfora FM, Lorenzo TD, et al. (2019) Does written informed consent adequately inform surgical patients? A cross sectional study. *BMC Med Ethics* 20: 340-344.
- 11 Prasad KGV (2020) Shared decision making in peri-operative medicine: Miles to go in Indian scenario. *J Anaesthesiol Clin Pharmacol* 36: 316-324.