

Incidence and Management of Arterial Anomalies in Patients Undergoing Pancreaticoduodenectomy

Azhar Perwaiz, Amanjeet Singh, Tanveer Singh, Adarsh Chaudhary

Department of Surgical Gastroenterology, Sir Ganga Ram Hospital. New Delhi, India

ABSTRACT

Context Pancreaticoduodenectomy entails ligation of vascular arcades arising from the celiac and superior mesenteric arteries. These are known to have anatomical variations. **Objective** This study was aimed at analyzing the spectrum of arterial anomalies and their clinical impact on the procedure itself. **Patients** The study includes 200 consecutive patients who underwent a pancreaticoduodenectomy between September 2003 and May 2009 after excluding those having distant metastases or local unresectability. **Main outcome measures** The records of the patients were studied to assess the incidence of arterial anomalies and the operative complexities involved in a pancreaticoduodenectomy. **Results** Fifty-three patients (26.5%) had arterial anomalies. The complexity of the surgery was determined by the course of these arteries. The mean duration of surgery was 420 ± 32.0 minutes in patients with arterial anomalies versus 370 ± 38.5 minutes in those with a normal arterial anatomy ($P=0.005$). Fifty-one out of 53 (96.2%) patients underwent pancreaticoduodenectomy with negative resection margins. The pancreaticoduodenectomy was abandoned in two cases due to patient- and tumor-related factors. **Conclusion** During pancreaticoduodenectomy, arterial anomalies can increase operative complexity but do not usually compromise the safety of the procedure or its oncological outcome.

INTRODUCTION

Pancreaticoduodenectomy (PD) is the standard surgical procedure for periampullary and pancreatic cancers. Ligation of the gastroduodenal artery and the pancreaticoduodenal arcade is necessary for its completion. The literature suggests that the normal pattern of hepatic artery anatomy is observed in 55 to 79% of patients [1, 2, 3 4]. The majority of the anomalous arteries originate from branches of either the celiac or the superior mesenteric artery and they are likely to have an abnormal course. These arterial anomalies can usually be identified by routine preoperative computed tomography scans but, in some patients, they become obvious only during surgery. Arterial anomalies assume importance as there is a chance of inadvertently damaging them during the procedure, compromising the vascular supply of the liver. In addition there is the chance of oncological compromise in an attempt to protect the anomalous or replaced arteries. This study aims to analyze the consequences that these anomalous arteries have on PD itself.

PATIENTS AND METHODS

The study included 200 consecutive patients who had resectable disease and underwent a PD by a single surgical team in a tertiary care centre. Detailed information regarding these patients was maintained on a prospective database. Demography and patient characteristics were carefully recorded. Pancreatic protocol contrast-enhanced computed tomography (CECT) was used for the preoperative assessment of resectability.

The details of the arterial anatomy, their variations, especially the origin, course and relationship to the pancreatic head, and the operative complexities during the procedure were carefully recorded. Anatomy was considered to be normal when the celiac axis trifurcated into the left gastric artery, the splenic artery and the common hepatic artery. The common hepatic artery continued as a hepatic artery proper after giving origin to the gastroduodenal artery and then bifurcated into the right and left hepatic arteries. The right hepatic artery arising from a source other than the hepatic artery proper in the absence of a normally located right hepatic artery was termed as a replaced right hepatic artery. An accessory right hepatic artery was defined as a right hepatic artery arising from a source other than the hepatic artery proper in the presence of a normally located right hepatic artery. A similar definition was used for an accessory left hepatic artery and a replaced left hepatic artery. Trifurcation anomaly was defined to be the left hepatic artery, the right hepatic artery and the gastroduodenal artery originating from the common

Received October 10th, 2009 - Accepted November 9th, 2009

Keywords Pancreaticoduodenectomy; Vascular Malformations

Correspondence Adarsh Chaudhary

Department of Surgical Gastroenterology, Room No. 2208A, Sir Ganga Ram Hospital, Old Rajinder Nagar, New Delhi 110060, India

Phone: +91-11.4225.2226; Fax: +91-11.2586.1002

E-mail: adarsh_chaudhary@yahoo.com

Document URL <http://www.joplink.net/prev/201001/13.html>

Table 1. Clinicopathological parameters of the patients (No. 200).

Indications for pancreaticoduodenectomy	
- Ampullary adenocarcinoma	83 (41.5%)
- Carcinoma of the head of the pancreas	47 (23.5%)
- Lower end cholangiocarcinoma	31 (15.5%)
- Duodenal carcinoma	15 (7.5%)
- Carcinoid	6 (3.0%)
- Gastrointestinal stromal tumor	3 (1.5%)
- Others	15 (7.5%)
- Arterial anomalies	53 (26.5%)
Detection of anomalies	
- Before surgery	38/53 (71.7%)
- During surgery	15/53 (28.3%)

hepatic artery without giving origin to the trunk of the hepatic artery proper.

After removal of the specimen, the resection margins were marked with ink. In cases where the abnormal artery passed close to the tumor or the transection line, the area in the specimen was marked intraoperatively with silk suture. Apart from the arterial anomalies, tumor size, duration of surgery, blood loss and additional resections (arterial or venous resection and reconstruction, multivisceral resection) were also documented. The reason for not performing a PD was recorded in particular when an arterial anomaly was present. Confirmation of the diagnosis and the resection margin status were recorded from the histopathological report of the specimen. All postoperative complications were recorded. Death during the same hospital stay or within 30 days of surgery was considered as operative mortality.

The endpoints of the study were to analyze the incidences and the operative complexities due to these abnormal arteries and to compare the patients having a normal arterial anatomy with those patients who underwent a PD.

ETHICS

Informed consent was obtained in all cases. The protocol was in accordance with the declaration of Helsinki and was approved by the institutional review board.

Table 2. Spectrum of arterial anomalies during pancreaticoduodenectomy (No. 200).

Anomalies	Mitchel type [3]	No. of cases
Normal anatomy	I	147 (73.5%)
Anomalous arterial anatomy		53 (26.5%)
- rRHA from SMA	III	29 (14.5%)
- aRHA from SMA	IV	6 (3.0%)
- aRHA from gastroduodenal artery	IV	3 (1.5%)
- rCHA from SMA anterior to the pancreas	IX	1 (0.5%)
- Trifurcation into GDA/RHA/LHA	Not classified	3 (1.5%)
- rLHA from the left gastric artery	II	8 (4.0%)
- aLHA from GDA	V	2 (1.0%)
- Celiac artery stenosis	Not classified	1 (0.5%)

aLHA: accessory left hepatic artery; aRHA: accessory right hepatic artery; GDA: gastroduodenal artery; LHA: left hepatic artery; rCHA: replaced common hepatic artery; RHA: right hepatic artery; rLHA: replaced left hepatic artery; rRHA: replaced right hepatic artery; SMA: superior mesenteric artery

STATISTICS

Data are reported as frequencies or mean±SD and ranges. The SPSS (version 17.0) software was used for data analysis. The Student t test was used to test significance for continuous variables and the Fisher’s exact test was used for categorical variables. Two-tailed P values less than 0.05 were considered significant.

RESULTS

Between September 2003 and May 2009, two hundred consecutive patients were included in the study. There were 148 (74.0%) males and 52 (26.0%) females with a mean age of 53.6±11.8 years (age range: 18-80 years). Pancreaticoduodenectomy was performed successfully in 198 (99.0%) patients. In the majority of cases, the indications were periampullary and pancreatic head cancer (Table 1). There were 53 (26.5%) arterial anomalies detected during the procedure. The spectrum of arterial anomalies was as shown in Table 2. Thirty-eight out of 53 (71.7%) anomalies were detected by preoperative CECT and the remaining 15 (28.3%) were found during the actual PD (Table 1). The course of these abnormal arteries varied according to their origin. All replaced right hepatic arteries or accessory right hepatic arteries arising from the superior mesenteric artery coursed posteriorly to the pancreatic parenchyma close to the head and uncinata process and then right posterolaterally to the common bile duct in the hepatoduodenal ligament. An anomalous artery from the gastroduodenal artery always looped down the superior border of the pancreas behind the neck and then coursed to the right or the left as a right or a left accessory or replaced hepatic artery respectively.

Effect of Arterial Anomalies on the Technical Aspects of the Surgery

Minimal difficulty during PD occurred in 11 (20.8%) cases. Three patients had trifurcation anomalies and 8

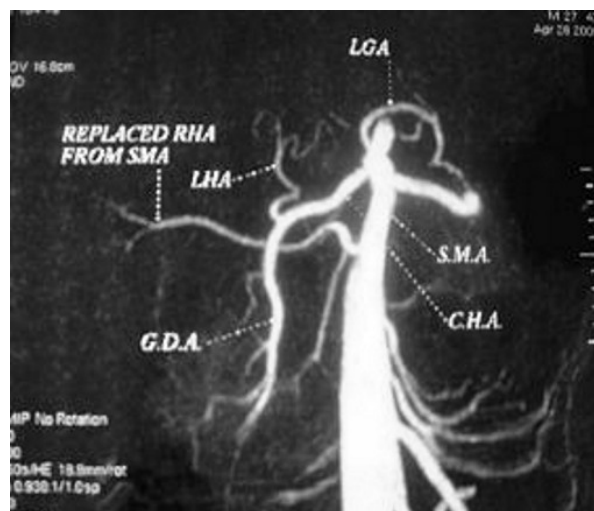


Figure 1. CT angiogram showing a replaced right hepatic artery arising from the superior mesenteric artery. CHA: common hepatic artery; GDA: gastroduodenal artery; LGA: left gastric artery; LHA: left hepatic artery; RHA: right hepatic artery; SMA: superior mesenteric artery

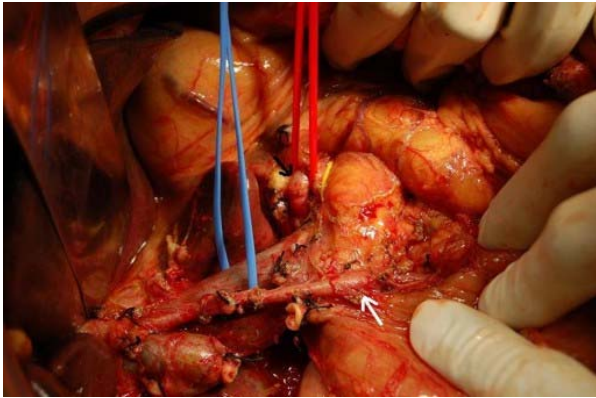


Figure 2. Replaced common hepatic artery (white arrow) coursing anteriorly to the pancreas. Celiac artery (black arrow) not giving origin to the common hepatic artery.

patients with replaced left hepatic arteries from the left gastric artery. The anomalous artery was coursing away from the field of transection. Pancreaticoduodenectomy was performed in all of them. No alteration or deviation of the procedure was necessary. Difficulty in removing the uncinate process and division of the common bile duct occurred in 35 (66.0%) cases. These were due to anomalous right hepatic arteries (accessory or replaced; Figure 1) arising from superior mesenteric artery. In one of these patients, the PD was abandoned. This patient had a replaced right hepatic artery arising from the superior mesenteric artery, encased by a 5.5 cm tumor arising from the head of the pancreas. Pancreaticoduodenectomy was technically possible with arterial reconstruction in this case, but it was abandoned due to the risk of a positive resection margin. Difficulty in transection at the neck of the pancreas occurred in 6 (11.3%) patients. There were 5 patients with anomalous arteries from the gastroduodenal artery (3 with an accessory right hepatic artery and 2 with an accessory left hepatic artery) and one patient with a replaced common hepatic artery from the superior mesenteric artery (Figure 2). Anomalous arteries from the gastroduodenal artery were closely associated with the posterosuperior surface at the level of the neck of the pancreas. Apart from the danger of injuring these arteries during pancreatic neck transection, there was difficulty in the ligation and division of the gastroduodenal artery and in creating a retropancreatic tunnel from the supraduodenal side. The gastroduodenal artery had to be dissected carefully, well below the origin of these abnormal arteries before it could be safely ligated and divided. One case was associated with an accessory left hepatic artery encased by a tumor; a PD with arterial division was performed without reconstruction as the test clamp of the anomalous artery showed preserved left hepatic arterial flow through the main left hepatic artery from the hepatic artery proper, which was confirmed by intraoperative Doppler ultrasound. In another patient, there was a replaced common hepatic artery arising from the superior mesenteric artery, coursing anteriorly

to the neck of the pancreas, associated with a 3 cm mass in the head. The vessel was separated from the tumor; it was looped using sharp dissection and the PD was completed. The area in the specimen was marked with silk sutures and histopathology reported it to be negative for a tumor.

The risk of compromising the hepatic arterial supply occurred in one (1.9%) patient. This 71-year-old patient had celiac artery stenosis (Figure 3), associated with a 6 cm mass in the head of the pancreas. The patient was known to have coronary artery disease. During surgery, it was found that the common hepatic artery from the celiac axis was small in size and the gastroduodenal artery was tortuous. A test clamp of the flow in the right and left hepatic arteries. A prominent pancreaticoduodenal arcade from the superior mesenteric artery was found coursing across the tumor and supplied the hepatic arteries through the gastroduodenal artery. All the major arteries (aorta, superior mesenteric artery and celiac axis) showed alterations due to atherosclerosis. The feasibility of PD with negative margins was remote and gastroduodenal artery reconstruction was not considered safe. Although PD was possible with reconstruction of the gastroduodenal artery, the procedure was abandoned due to patient- and tumor-related factors.

Overall, in only 2 out of 53 (3.8%) patients with arterial anomalies was the PD abandoned (one case of a replaced right hepatic artery from the superior mesenteric artery encased by the tumor and another patient with celiac artery stenosis). The reason for abandoning PD in these patients was related to the size of the tumor (greater than 5 cm), the risk of positive resection margins, the advanced age of the patient with coronary artery disease and atherosclerosis, and was not related to the abnormal artery itself.

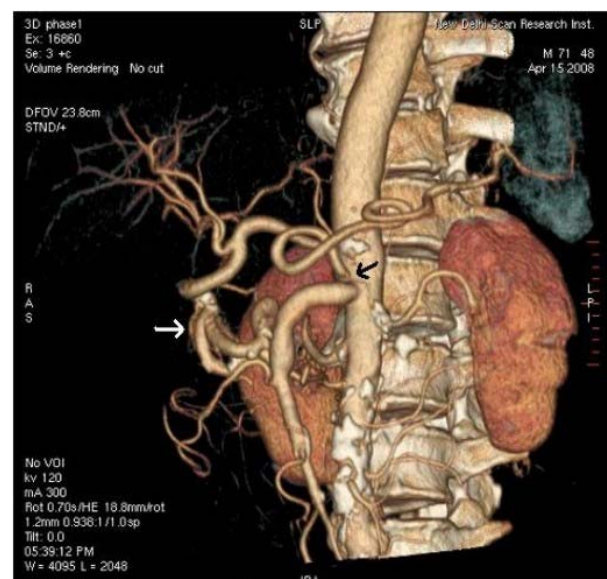


Figure 3. Celiac artery stenosis (black arrow) with tortuous pancreaticoduodenal arcade (white arrow). Atherosclerotic changes in the major arteries.

Comparison of Patients with and without Arterial Anomalies

The mean blood loss in the group with arterial anomalies was 450±54 mL (range: 270-630 mL) and in those without arterial anomaly was 415±61 mL (range: 290-540 mL) (P<0.001). The patients with arterial anomalies had a prolonged operating time. The mean duration of surgery was 420±32 minutes (range: 300-540 minutes) in patients with arterial anomaly versus 370±38 minutes (range: 240-500 minutes) in those without arterial anomalies (P=0.005). The mean duration of surgery was 412±35 minutes (range: 315-510 minutes) in the 38 patients who underwent PD with preoperatively known arterial anomalies *versus* 420±44 minutes (range: 300-540 minutes) in those (no. 15) where the arterial anomalies were detected during surgery (P=0.489).

The overall complication rate, mortality and length of hospital stay were not significantly different between the two groups (Table 3). Eleven (5.6%) out of 198 PD specimens had positive resection margins (9 retroperitoneal margins defined as the rim of the connective tissue being rich in lymphatics and nerve plexus separating the uncinate process from the superior mesenteric artery, and 2 common bile duct margins). No patient with arterial anomalies had positive resection margins.

DISCUSSION

Celiac and mesenteric axes are known for anatomical variations. Knowledge of the hepatic arterial blood supply is essential when planning a PD in order to avoid unnecessary surgical complications. Almost all anomalous arteries are known to have some variation in their course. These arteries may lie close to the tumor and can be damaged during the dissection or tumor cell spillage may occur. Variations in hepatic arterial anatomy are known to range from 21 to 45% [1, 2, 3, 4]. In our experience, the incidence of arterial anomalies was 26.5%. The limitation of our study is that the reported incidences of arterial anomalies may not be a true representation of anomalies in general as we did not routinely perform a preoperative CT angiogram or selective mesenteric angiography;

however, the overall spectrum of our arterial anomalies matches well with a recent report [5].

Anomalous right hepatic artery is reported to be the most common arterial anomaly encountered during PD [5]. Our study suggests that 35 (66.0%) of all arterial anomalies were anomalous right hepatic arteries of which the majority were replaced right hepatic arteries arising from the superior mesenteric artery. These arteries lie close to the uncinate process and course posterolaterally to the hepatoduodenal ligament. It is necessary to identify them routinely before proceeding to resection of the pancreatic head and the uncinate process and also when the common bile duct is dissected and divided. The presence of these anomalies adds to the operative complexities, although this finding was not supported by a recent report by Jah *et al.* [6] which showed that the presence of aberrant right hepatic arteries was not associated with a significant increase in operative complexities but was a trend towards a prolonged operating time; more intraoperative blood loss was noted in patients with aberrant right arteries undergoing PD. We were able to perform PD in all of them except in one case where the artery was encased by the large tumor and the procedure was abandoned due to the tumor-related factors rather than due to the presence of the anomalous artery itself.

A replaced common hepatic artery from the superior mesenteric artery represents the variation commonly known as hepatomesenteric trunk [3, 7]. The replaced common hepatic artery may ascend along the ventral side of the pancreas (as in our series), between the pancreas and the portal vein, behind the portal vein or through the head of the pancreas. A PD preserving these arteries in patients with ampullary cancer is reported to be safe [8]. We managed to preserve the artery while performing a PD by separating and isolating it away from the tumor. This was possible due to the small size of the tumor and no gross involvement of the anomalous artery. There is a risk of tumor cell spillage while coring the anomalous artery out of the pancreatic capsule and the possibility of the transection line deviating to the right side while dividing the neck of the pancreas, leading to positive pancreatic resection margins [9, 10, 11]. Other possible options are either to

Table 3. Comparison of patients with or without arterial anomalies (No. 200).

Variables	Patients with arterial anomalies (No. 53)	Patients without arterial anomalies (No. 147)	P value
Overall complications	16 (30.2%)	43 (29.3%)	1.000^b
- Pancreatic fistula	5 (9.4%)	12 (8.2%)	0.777 ^b
- Delayed gastric emptying	3 (5.7%)	11 (7.5%)	0.764 ^b
- Wound infection	3 (5.7%)	6 (4.1%)	0.702 ^b
- Bile leak	1 (1.9%)	4 (2.7%)	1.000 ^b
- Intestinal fistula	1 (1.9%)	2 (1.4%)	1.000 ^b
- Abdominal bleed	1 (1.9%)	2 (1.4%)	1.000 ^b
- Others	1 (1.9%)	3 (2.0%)	1.000 ^b
- Mortality	1 (1.9%)	3 (2.0%)	1.000 ^b
Duration of surgery ^a (minutes)	414±37 (300-540)	370±38 (240-500)	<0.001 ^c
Operative blood loss ^a (mL)	450±54 (270-630)	415±61 (290-540)	<0.001 ^c
Length of hospital stay ^a (days)	10.6±6.0 (4-27)	9.9±5.1 (4-26)	0.462 ^c

^a mean±SD (range)

^b Fisher's exact test; ^c Student t test

sacrifice the artery or to reconstruct it in order to complete the procedure. Ligation of a replaced common hepatic artery can cause liver necrosis as these anomalous arteries are usually end arteries [12]. However, surgical experience with biliary tract malignancy shows that the right branch of the hepatic artery can be safely ligated without reconstruction provided the collateral arteries in the Glissonian sheath around the hepatic duct confluence are preserved [13]. Transient ischemic liver damage without serious postoperative complications has been reported when the PD was performed, ligating the replaced common hepatic artery without reconstruction [8] but experience is limited to a small number of patients. Reconstruction using an autologous vein or Gore-Tex interposition grafts is a reasonable option in these circumstances but it is reported to be associated with an inherent risk of potentially fatal postoperative bleeding if a pancreatic fistula develops [14, 15, 16, 17].

In the case of celiac artery stenosis, division of the gastroduodenal artery poses an ischemic threat to the liver and biliary reconstruction. Such anomalies are found in 1 to 3% of PDs [18]. Celiac artery stenosis in the majority of patients is associated with atherosclerotic narrowing and adequate collateral arteries may coexist in up to 80% of cases [19, 20]. Ligation of the gastroduodenal artery is tolerated in such a situation as the hepatopetal arterial flow is preserved due to the alternate collateral pathways and a PD can be performed successfully without reconstruction as reported by Trede [18]. However, if the collaterals are inadequate, arterial reconstruction is needed [21]. Test occlusion of the gastroduodenal artery with diminished pulsation in the hepatic artery, as recommended by Bull *et al.* [22] is a reasonable guide to ligate or to reconstruct the gastroduodenal artery during a PD. Other possible options to deal with celiac artery stenosis are preoperative endovascular stents [23, 24, 25], balloon dilatation [26], release of median arcuate ligaments [22] and intraoperative revascularization [21, 27, 28]. A gastroduodenal artery-preserving PD has been described [29], particularly in benign conditions such as chronic pancreatitis [21], but it has limited application in pancreatic and periampullary malignancies because this could compromise the resection margins.

The overall postoperative complication after PD did not attain a statistically significant difference except for the duration of surgery in patients with or without arterial anomaly in our study, which is well supported by a recent report by Jah *et al.* [6]. However, the author in this study showed no statistical difference in operating time, but a trend towards a prolonged operating time was noted in patients undergoing a PD with arterial anomaly. The incidence of postoperative complications, operating time and blood loss reported in the current study is similar to what has been reported in another recent report by Yang *et al.* [5].

Arterial anomalies encountered during a PD are common. There is a need to identify them routinely and

prevent inadvertent damage. Their presence can increase the operative complexity as reflected by the longer duration of the surgery. Interestingly, the duration of the surgery did not differ significantly between those patients whose arterial anomalies could be detected preoperatively and those which were detected intraoperatively.

Conflict of interest The authors have no potential conflicts of interest

References

1. Kooops A, Wojciechowski B, Broering DC, Adam G, Krupski-Berdien G. Anatomic variations of the hepatic arteries in 604 selective celiac and superior mesenteric angiographies. *Surg Radiol Anat* 2004; 26:239-44. [PMID 14968265]
2. Covey AM, Brody LA, Maluccio MA, Getrajdman GI, Brown KT. Variant hepatic arterial anatomy revisited: digital subtraction angiography performed in 600 patients. *Radiology* 2002; 224:542-7. [PMID 12147854]
3. Michels NA. Newer anatomy of the liver and its variant blood supply and collateral circulation. *Am J Surg* 1966; 112:337-47. [PMID 5917302]
4. Soin AS, Friend PJ, Rasmussen A, Saxena R, Tokat Y, Alexander GJ, et al. Donor arterial variations in liver transplantation: management and outcome of 527 consecutive grafts. *Br J Surg* 1996; 83:637-41. [PMID 8689206]
5. Yang F, Long J, Fu DL, Jin C, Yu XJ, Xu J, et al. Aberrant hepatic artery in patients undergoing pancreaticoduodenectomy. *Pancreatol* 2008; 8:50-4. [PMID 18230918]
6. Jah A, Jamieson N, Huguette E, Praseedom R. The implications of the presence of an aberrant right hepatic artery in patients undergoing a pancreaticoduodenectomy. *Surg Today* 2009; 39:669-74. [PMID 19639433]
7. Higashi N, Hirai K. On the hepatic artery arising from the superior mesenteric artery. *Kaibogaku Zasshi* 1995; 70:338-46. [PMID 8540282]
8. Yang SH, Yin YH, Jang JY, Lee SE, Chung JW, Suh KS, et al. Assessment of hepatic arterial anatomy in keeping with preservation of the vasculature while performing pancreaticoduodenectomy: an opinion. *World J Surg* 2007; 31:2384-91. [PMID 17922256]
9. Yamamoto S, Kubota K, Rokkaku K, Nemoto T, Sakuma A. Disposal of replaced common hepatic artery coursing within the pancreas during pancreaticoduodenectomy: report of a case. *Surg Today* 2005; 35:984-7. [PMID 16249858]
10. Woods MS, Traverso LW. Sparing a replaced common hepatic artery during pancreaticoduodenectomy. *Am Surg* 1993; 59:719-21. [PMID 7902051]
11. Furukawa H, Shimada K, Iwata R, Moriyama N. A replaced common hepatic artery running through the pancreatic parenchyma. *Surgery* 2000; 127:711-2. [PMID 10840370]
12. Kayaalp C, Nessar G, Kaman S, Akoglu M. Right liver necrosis: complication of laparoscopic cholecystectomy. *Hepatogastroenterology* 2001; 48:1727-9. [PMID 11813609]
13. Miyazaki M, Ito H, Nakagawa K, Ambiru S, Shimizu H, Yoshidome H, et al. Unilateral hepatic artery reconstruction is unnecessary in biliary tract carcinomas involving lobar hepatic artery: implications of interlobar hepatic artery and its preservation. *Hepatogastroenterology* 2000; 47:1526-30. [PMID 11148993]
14. Li B, Chen FZ, Ge XH, Cai MZ, Jiang JS, Li JP, Lu SH. Pancreatoduodenectomy with vascular reconstruction in treating carcinoma of the pancreatic head. *Hepatobiliary Pancreat Dis Int* 2004; 3:612-5. [PMID 15567757]
15. Nakano H, Bachellier P, Weber JC, Oussoultzoglou E, Dieng M, Shimura H, et al. Arterial and vena caval resections combined with pancreaticoduodenectomy in highly selected patients with

periapillary malignancies. *Hepatogastroenterology* 2002; 49:258-62. [PMID 11941970]

16. Kondo S, Katoh H, Hirano S, Ambo Y, Tanaka E, Okushiba S, Morikawa T. Results of radical distal pancreatectomy with en bloc resection of the celiac artery for locally advanced cancer of the pancreatic body. *Langenbecks Arch Surg* 2003; 388:101-6. [PMID 12684805]

17. Bold RJ, Charnsangavej C, Cleary KR, Jennings M, Madray A, Leach SD, et al. Major vascular resection as part of pancreaticoduodenectomy for cancer: radiologic, intraoperative, and pathologic analysis. *J Gastrointest Surg* 1999; 3:233-43. [PMID 10481116]

18. Trede M. The surgical treatment of pancreatic carcinoma. *Surgery* 1985; 97:28-35. [PMID 2578229]

19. Thompson NW, Eckhauser FE, Talpos G, Cho KJ. Pancreaticoduodenectomy and celiac occlusive disease. *Ann Surg* 1981; 193:399-406. [PMID 7011224]

20. Song SY, Chung JW, Kwon JW, Joh JH, Shin SJ, Kim HB, Park JH. Collateral pathways in patients with celiac axis stenosis: angiographic-spiral CT correlation. *Radiographics* 2002; 22:881-93. [PMID 12110717]

21. Berney T, Pretre R, Chassot G, Morel P. The role of revascularization in celiac occlusion and pancreatoduodenectomy. *Am J Surg* 1998; 176:352-6. [PMID 9817254]

22. Bull DA, Hunter GC, Crabtree TG, Bernhard VM, Putnam CW. Hepatic ischemia, caused by celiac axis compression, complicating pancreaticoduodenectomy. *Ann Surg* 1993; 217:244-7. [PMID 8095781]

23. Sharafuddin MJ, Olson CH, Sun S, Kresowik TF, Corson JD. Endovascular treatment of celiac and mesenteric arteries stenoses: applications and results. *J Vasc Surg* 2003; 38:692-8. [PMID 14560214]

24. van Wanroij JL, van Petersen AS, Huisman AB, Mensink PB, Gerrits DG, Kolkman JJ, Geelkerken RH. Endovascular treatment of chronic splanchnic syndrome. *Eur J Vasc Endovasc Surg* 2004; 28:193-200. [PMID 15234701]

25. Hasegawa K, Imamura H, Akahane M, Miura Y, Takayama T, Ohtomo K, et al. Endovascular stenting for celiac axis stenosis before pancreaticoduodenectomy. *Surgery* 2003; 133:440-2. [PMID 12717363]

26. Machado MC, Penteado S, Montagnini AL, Machado MA. An alternative technique in the treatment of celiac axis stenosis diagnosed during pancreaticoduodenectomy. *HPB Surg* 1998; 10:371-3. [PMID 9515234]

27. Okamoto H, Suminaga Y, Toyama N, Konishi F, Kawahito H. Autogenous vein graft from iliac artery to splenic artery for celiac occlusion in pancreaticoduodenectomy. *J Hepatobiliary Pancreat Surg* 2003; 10:109-12. [PMID 12918470]

28. Manabe T, Baba N, Setoyama H, Ohshio G, Tobe T. Venous bypass grafting for celiac occlusion in radical pancreaticoduodenectomy. *Pancreas* 1991; 6:368-71. [PMID 1862070]

29. Nagai H, Ohki J, Kondo Y, Yasuda T, Kasahara K, Kanazawa K. Pancreatoduodenectomy with preservation of the pylorus and gastroduodenal artery. *Ann Surg* 1996; 223:194-8. [PMID 8597514]