

DOI: 10.36648/2248-9215.10.1.100

Histochemical Effects of Aloe Vera Gel (*Aloe barbadensis* Miller) on Puncture-Induced Intervertebral Disc Degeneration in Rabbits

Akinola Kolade Busuyi^{1*}, Abiodun Adegboyega Adeleke², Olawuyi Toluwase Solomon¹, Omole Joseph Gbenga³ and Akinola Priscilla Adebimpe⁴

¹Department of Anatomy, School of Health and Health Technology, Federal University of Technology, Akure, Nigeria

²Department of Anatomy and Cell Biology, Obafemi Awolowo University, Ile-Ife, Osun State, Nigeria

³Department of Physiological Sciences, Obafemi Awolowo University, Ile-Ife, Nigeria

⁴Department of Biology, School of Sciences, Federal University of Technology, Akure, Nigeria

*Corresponding author: Akinola Kolade Busuyi, Department of Anatomy, School of Health and Health Technology, Federal University of Technology, Akure, Nigeria, Tel: +2348032073693; E-mail: bkakinola@futa.edu.ng

Received Date: January 13, 2020; Accepted Date: January 23, 2020; Published Date: January 31, 2020

Copyright: © 2020 Busuyi AK, et al. This is an open-access article distributed under the terms of the Creative Commons Attribution License, which permits unrestricted use, distribution, and reproduction in any medium, provided the original author and source are credited.

Citation: Busuyi AK, Adeleke AA, Solomon OT, Gbenga OJ, Adebimpe AP (2020) Histochemical Effects of Aloe Vera Gel (*Aloe barbadensis* Miller) on Puncture-Induced Intervertebral Disc Degeneration in Rabbits. Eur Exp Biol Vol.10 No.1:3.

Abstract

Aim: This study is aimed at investigating the effects of Aloe Vera Gel (AVG) on the histochemical parameters of an annular-punctured rabbit.

Methods: Twenty-five rabbits weighing 1.0-3.5 kg were subjected to annular puncture of the L3/L4, L4/L5 and L5/L6 Intervertebral Discs (IVD) using an 18G needle. Rabbits were assigned into five groups (A, B, C, D, and E) with five animals per group. Group A was not punctured. Group B was punctured. Groups C, D, and E were punctured and received AVG. The administration was via oral cannula for 6 weeks. At the end of the experiment, samples were obtained for biochemical and immunochemical analysis with tissue samples excised for histological procedures.

Results: The results showed a significant increase ($F=7.08$; $p=0.012$) in the serum level of Superoxide Dismutase (SOD) and decrease ($F=10.20$; $p=0.0001$) in the concentration of Malondialdehyde (MDA). We found a significant increase in concentrations of both interleukin 1β ($F=7.36$; $P=0.0008$) and Tumor Necrosis Factor (TNF) α ($F=37.46$; $p=0.0001$). AVG was also able to repair damaged IVD by restoring the histoarchitecture of the nucleus pulposus and annulus fibrosus.

Conclusion: We conclude that AVG can repair damaged intervertebral disc and has a strong anti-oxidative and immune-modulatory properties in an annular-punctured rabbit.

Keywords: Intervertebral disc; Interleukins; Tumor necrosis factor; Annulus fibrosus

Introduction

Over the years, the Aloe Vera herb has been renowned for its functions in medicine, its healing properties, and its cosmetic benefits to man. Its therapeutic applications have been enormous in numerous cultures such as Greece, Egypt, India, Mexico, Japan, and China [1]. Belonging to the *Asphodelaceae* (Liliaceae) family, the Aloe Vera (botanical name: *Aloe barbadensis* Miller) grows generally in the dry climates of Africa, Asia, Europe and America [1]. There are two major parts to which the Aloe Vera leaf can be divided into; they are the outer green rind (which contains the vascular bundles) and the inner colorless parenchyma (which contains the aloe gel). It might be quite challenging to describe the inner central region of the Aloe Vera leaf because of some terms such as inner pulp, mucilage tissue; mucilaginous gel, mucilaginous jelly, inner gel, and leaf parenchyma tissue are usually substituted for each other. Technically, the term 'pulp' or 'parenchyma tissue' refers to the intact fleshy inner part of the leaf including the cell walls and organelles, while 'gel' or 'mucilage' refers to the viscous clear liquid within the parenchyma cells [2].

The anti-oxidant effects of both the different fractions of Aloe Vera and the unfractionated whole gel have gained literary attention though several authors due to the likely activities or functions of the enzymes- Glutathione peroxidase, superoxide dismutase, and a phenolic anti-oxidant present in Aloe Vera [3]. Another effect of the Aloe Vera gel is the inhibition of prostaglandin E2 production from inflamed colorectal biopsies; however, it had no effect on thromboxane B2 release [2]. Furthermore, Aloe Vera gel exhibits anti-

inflammatory properties by reduction of inflammation induced by the production of agents that promote prostaglandin synthesis as well as increased infiltration of leucocytes; however, it is less effective against inflammation caused by agents that produce allergic reactions [4]. It is also claimed that Aloe Vera through its components (glucomannan) stimulates fibroblast activity and proliferation and hence raises collagen production after topical and oral application [1].

Materials and Methods

Materials

The Aloe Vera (*Aloe barbadensis* Miller) used was obtained from the Herbarium of the Pharmacognosy Department in the Faculty of Pharmacy, Obafemi Awolowo University, Ile Ife. A Taxonomist authenticated it. The materials used for surgical procedures are chromic suture, silk suture, surgical set with blades, gauze bandage, savlon, methylated spirit, ketamine (Pfizer, 235 East 42nd Street, New York, USA), Diazepam (Bayer HealthCare LLC, Shawnee Mission, USA), 18G free needle, 2CC needle and syringe, 5CC needle and syringe. Equipment used are Microtome (Leica RM 2125 RTS), Centrifuge (Denly, Model BS 400), Metler's sensitive balance (Metler Toledo, Mg 126), Automatic tissue processor, 96-microplate reader (model SM 600, China), water bath (model MH-8504), adjustable Pipettes (Surepette RS 16013), ELISA kit (Elabscience®, USA, Catalog No: E-EL-R0012).

Experimental animal

The study was done using twenty-five New Zealand Rabbits (18 males and 7 females) weighing 1.5-2.5 kg (3-4 months old). These Rabbits were obtained from the Faculty of basic medical sciences, Obafemi Awolowo University, Ile Ife and kept in a well-ventilated animal house under a standard condition of humidity, temperature, and light. The animals were handled in accordance with the institutional guidance and rules on animal care. Each animal was fed with standard rabbit chow (vital feed, Ile Ife) and allowed access to water ad libitum. Prior to the experiment, all the animals were allowed to acclimatize for two weeks.

Surgical technique

The surgical technique used was according to Young-Joon procedure [5]. Each rabbit furs was first shaved from the inferior border of the scapula and left flank to the iliac crest. An intramuscular injection containing diazepam (1 mg/kg) and ketamine (35 mg/kg) was used to anesthetize the rabbits. The Rabbits were then placed in the lateral oblique position and a 5 cm lateral skin incision was made between the last rib and the iliac crest. The entire lumbar spine was then exposed through blunt dissection of muscles and retroperitoneal space. The first two lumbar discs (L1/L2 and L2/L3) were left intact for control purposes while the three most caudal IVDs were punctured with 18G needles first at the center then 2 cm right and left of the central puncture. Each puncture was rotated 180° clockwise and kept in position for 30 seconds. After the

annular puncture, the retroperitoneal space was washed with saline solution, and the muscles, as well as the skin, sutured. The rabbits were then allowed to recover from anesthesia before being transferred to the cages.

Plant preparation

Mature, healthy and fresh Aloe Vera leaves were harvested from the medicinal garden of the faculty of Pharmacy, Obafemi Awolowo University, Ile-Ife. The thick epidermis was carefully removed after the leaves were washed with fresh water. Using an electric blender, the mucilaginous gel was homogenized and the homogenate was concentrated by filtration using Whatman paper 2 and freeze-dried. The thickened concentrated gel and the filtrate were kept at 4°C for use.

Experimental design

All the rabbits were randomly assigned into five groups (A, B, C, D, and E) with five animals in each group to ensure even distribution of mean body weight across groups. Group A received oral administration of normal saline (1 ml/kg) daily for 6 weeks but was not punctured. Group B received oral administration of normal saline (1 ml/kg) daily for 6 weeks after a puncture. Group C also received oral administration of 600 mg/kg Aloe Vera leaf gel daily for 6 weeks after a puncture. Group D received an oral administration of 400 mg/kg Aloe Vera leaf gel daily for 6 weeks after a puncture. Group E received oral administration of 200 mg/kg Aloe Vera leaf gel daily for 6 weeks after a puncture. The thickened paste of Aloe Vera was weighed and dissolved in its filtrate for oral administration by a suitable oral cannula.

Sample collection

Twenty-four hours before the sacrifice of the rabbits, blood samples were obtained through the left auricular venous puncture. The blood samples obtained were collected in 5 ml plain bottles and were centrifuged for 15 minutes at 2000 rpm. Thereafter, the supernatants were decanted into another plain bottle for biochemical and immunochemical analysis. The entire lumbar spine was also excised for histological analysis after sacrificing via cervical dislocation.

Biochemical analysis

Measurement of superoxide dismutase (SOD): The level of SOD activity was determined by the method of Misra and Fridovich [6].

Assessment of serum malondialdehyde (MDA): This was determined by measuring the Thiobarbituric Acid Reactive Substances (TBARS): a product of lipid peroxidation using the Varshney and Kale [7] method.

Immunochemical procedure

Determination of interleukin-1 β (IL-1 β): IL-1 β was quantitatively assayed using the ELISA method {an Avidin-

Horseshoe Peroxidase (HRP) and Biotin antigen-antibody reaction complex principle}.

Determination of tumor necrosis factor (TNF- α): This was done by antigen-antibody reaction methods using Enzyme-Linked Immunosorbent Assay (ELISA) from Bioassay Technology Laboratory, the USA with Cat. No E0003Ra the concentration of TNF- α was measured in pg/mL.

Histological analysis

The intact specimens of the sacrificed rabbits were fixed with 10% formaldehyde. Histological analysis for collagen fibers was done using the Vialle et al. [4] procedure. The punctured discs and the non-punctured discs were harvested for histological analyses. The harvested tissues were fixed with 10% neutral buffered formalin for 48 hours and decalcified in decalcification solution (10% EDTA) for 5 days. The decalcified specimen was then processed for paraffin sectioning. Blocks embedded in paraffin were cut into mid-sagittal sections (5 μ m in thickness) with a microtome. The sections were then stained with Masson Trichrome to demonstrate collagen fibers.

Statistical analysis

Data were analyzed using a One-Way Analysis Of Variance (ANOVA) followed by the Students Newman-Keuls (SNK) test for multiple comparisons. Results were expressed as Mean \pm SEM, $p < 0.05$ was taken as an acceptable level of significant difference.

Results

Effects of Aloe Vera gel on superoxide dismutase (SOD)

Figure 1 illustrates the end results of the use of Aloe Vera gel on SOD activity in the serum of rabbits with puncture-induced intervertebral disc degeneration. A huge decrease ($p < 0.005$) occurred in the serum level of SOD in group B rabbits when compared with the normal control (group A). The serum level of SOD is also significantly different when comparing the treated groups with a non-treated group (group B). However, no significant difference occurred among the treated groups when they were compared with each other.

Influence of Aloe Vera gel on malondialdehyde (MDA)

Figure 2 showed how Aloe Vera gel influenced the serum MDA level of puncture-induced intervertebral disc degeneration in rabbits. There was a huge decrease ($p < 0.05$) in the serum levels of MDA in the treated rabbits caused by the Aloe Vera gel when compared to the punctured but not treated group (group B). No significant difference occurred between the group with the highest dose of Aloe Vera gel (group C) and the normal control (group A). However, low dose Aloe Vera gel did not significantly reduce lipid peroxidation in

rabbits with IVD injury as there is no significant difference from the negative control (group B).

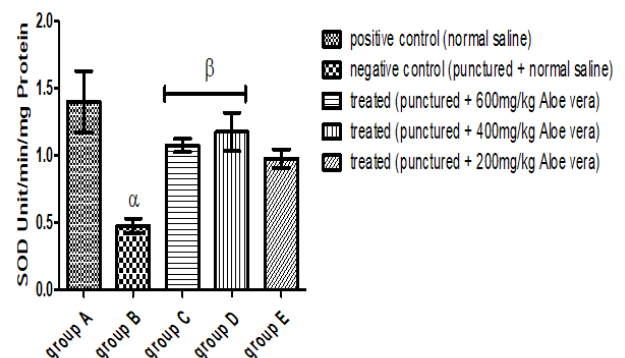


Figure 1: Effects of Aloe Vera gel on serum SOD activity. Each value represented Mean \pm SEM, $n = 5$ readings. The value of $p < 0.05$ was considered significant. The values with superscript α = significantly different from group A, β = significantly different from group B. SOD: Superoxide Dismutase.

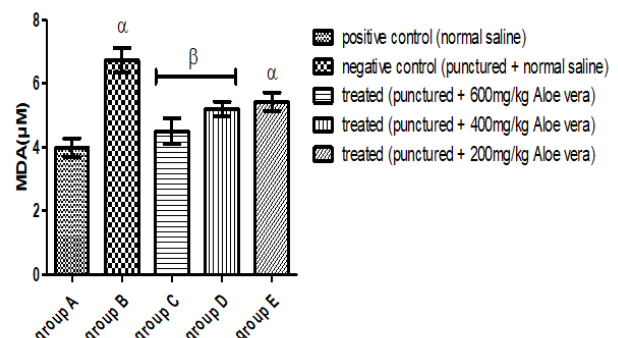


Figure 2: Effects of Aloe Vera gel on serum lipid peroxidation product (Malondialdehyde MDA). Each value represented Mean \pm SEM, $n = 5$ readings. The value of $p < 0.05$ was considered significant. The values with superscript α = significantly different from group A, β = significantly different from group B.

Influence of Aloe Vera gel on pro-inflammatory cytokines

The concentrations of both IL-1 β and TNF- α appears to be significantly up-regulated among the treated groups in this study as seen in **Figures 3 and 4** below. There is an observed significant difference in the concentrations of the cytokines in the treated groups when compared to the non-treated groups. The values are significantly higher in the treated groups compared to the non-treated groups. There exists no significant difference however in the concentrations of these cytokines when comparing the normal control group A (non-

punctured group) with the negative control group B (punctured but not treated group).

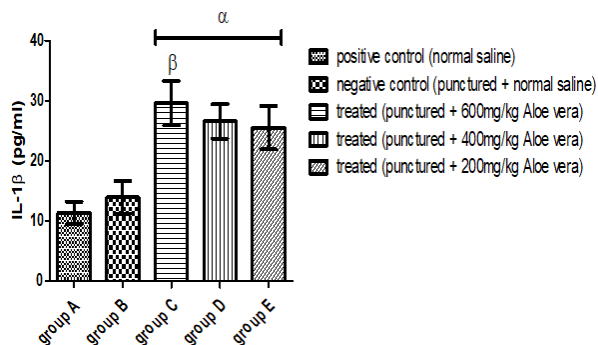


Figure 3: Showed the effects of Aloe Vera gel on IL-1 β cytokine. Each value represented Mean \pm SEM, n=5 readings. The value of p0.05 was considered significant. The values with superscript α =significantly different from group A, β =different from group B.

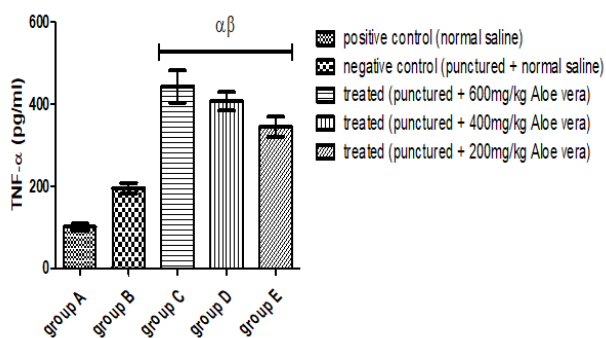


Figure 4: Showed the effects of Aloe Vera gel on TNF- α cytokine. Each value represented Mean \pm SEM, n=5 readings. The value of p0.05 was considered significant. The values with superscript α =significantly different from group A, β =different from group B.

Effects of AVG on the collagen fibers of IVD

Figure 5 shows the photomicrograph of IVD sections subjected to Masson Trichrome stain to demonstrate collagen fibers. Group A showed a normal histological pattern of collagen both in morphology and integrity in the annulus fibrosus whereas there is a complete disruption of collagen organization in group B while the gradual restoration was observed in the treated groups C, D, and E in a dose-dependent manner.




Figure 5: Showing the photomicrograph of IVD collagen fibers in groups A, B, C, D and E. The presence and organization of collagen fibers in AF appears distorted in group B showing degeneration. Groups C, D and E showed the varying extent of repair and reorganization of collagen. Stain: Masson Trichrome; Magnification 40X. VEP: Vertebral Endplate; AF: Annulus Fibrosus; NP: Nucleus Pulposus.

Discussion

Oxidative stress no doubts a component of the mechanism of damage in disc degeneration [4]. An increased mechanical loading leading to an annulus tear setting up a cascade of reaction is another major cause of disc degeneration [8]. It has been established that the electron-emitting oxidation of metabolic intermediates can lead to the production of ROS at specific sites in the mitochondria. The transfer of a single electron to O₂ yields superoxide (O₂⁻) which is converted to hydrogen peroxide (H₂O₂) by superoxide dismutase in the matrix. This can oxidize proteins, lipids or mitochondrial DNA [9]. The result of this interaction is the release of proteolytic enzymes of the cell lysosomes and apoptotic enzymes of the mitochondrial matrix causing disc matrix degradation with typical morphological changes [10-12].

This study found that AVG significantly reduced the end result of lipid peroxidation product (Malondialdehyde MDA) and enhances the action of Superoxide Dismutase (SOD) suggesting a strong anti-oxidative property of the gel [3,13,14]. This supports a report that following administration of AVG, metallothionein (an antioxidant protein) was generated in the skin where it scavenged hydroxyl radicals and prevented the suppression of superoxide dismutase and glutathione peroxidase in the skin [15-17]. Superoxide dismutase and some other important anti-oxidants have been isolated from the gel of Aloe Vera [9,18]. This could explain our findings in

this study where the activity of SOD was significantly enhanced and the concentration of MDA was significantly reduced.

In almost all tissues, after traumatic damage, there is an inherent release of inflammatory mediators that help with tissue repair. Our findings in this study thus show that Aloe Vera gel enhances the activities of both IL-1 β and TNF- α very important pro-inflammatory mediators. This is due to the action of acemannan, a compound found in Aloe Vera that stimulates the production and release of IL-1 and TNF- α from macrophages which in turn initiated an immune attack against malignant cells [13,15,18]. It has also been reported that a new (but original) anti-inflammatory compound called C-glucyl chrome which inhibits the cyclo-oxygenase pathway and limits prostaglandin E2 production from Arachidonic Acid was isolated from AVG [13-15,19,20].

Histological evaluation of the IVD sections 6 weeks after administration of Aloe Vera gel revealed that the degenerative process was ameliorated. Notable progression in disc degeneration was observed in the annular punctured but saline administered group with most of the NP content lost and collapsed and disorganization of the collagen content of the AF in contrast to the Aloe Vera gel administered group where we observed a resemblance to normal IVD status. These findings are in no doubt due to the healing ability of Aloe Vera gel as reported by previous researches. It has also been reported that Aloe Vera increased in a significant manner the collagen content of granulating tissue and enhances the expression of collagen type III [11,18]. This explains while we observed a significant repair of damaged IVD following administration of Aloe Vera gel in this study.

Conclusion

Our findings in this study validate the claim that AVG is a potent anti-oxidative agent. Prolonged administration of AVG will enhance the serum expression of pro-inflammatory mediators such as IL-1 β and TNF- α . This suggests therefore that the anti-inflammatory activity Aloe Vera is by inhibition of the cyclo-oxygenase pathway rather than inhibition of pro-inflammatory mediators. We also conclude that Aloe Vera gel will accelerate the repair of the damaged intervertebral disc and may be useful in discogenic low back pain.

Ethical Standard

Ethical approval was obtained from the Health, Research, and Ethics Committee (HREC) of the Institute of Public Health, Obafemi Awolowo University, Ile-Ife.

Conflict of Interest

The authors declare that there is no conflict of interest.

Funding

This work was self-sponsored.

Acknowledgment

The authors like to acknowledge the Department of Anatomy and Cell Biology, Obafemi Awolowo University, Ile Ife and Mr. Isaac Ifeoluwa Ogunlowo of the Department of Pharmacognosy, Obafemi Awolowo University, Ile Ife for helping with identification and indexing of the plant material.

References

1. Malek VG, Abbasian A, Karimi M, Khanlarkhani N, Parvari S (2017) 5 medicinal plants used in Iranian traditional medicine for low back pain: a quick review. *Eur Exp Biol* 7: 24.
2. Hamman JH (2008) Composition and application of Aloe Vera leaf gel. *Molecules* 13: 1599-1616.
3. Joseph B, Raj SJ (2010) Pharmacognostic and phytochemical properties of Aloe Vera: an overview. *Int J Pharm Sci Rev Res* 4: 106-110.
4. Vialle EN, Vialle LRG, Arruda OA (2012) Histomorphometric analysis of experimental disc degeneration. *Global Spine J* 2: 129-136.
5. Kwon YJ (2013) A minimally invasive Rabbit Model of progressive and reproducible disc degeneration confirmed by radiology, gene expression and histology. *J Korean Neurosurg Soc* 5: 323-330.
6. Misra HP, Fridovich I (1972) The role of superoxide anion in the autoxidation of epinephrine and a simple assay for superoxide dismutase. *J Biol Chem* 247: 3170-3175.
7. Vashney R, Kale RK (1990) Effects of calmodulin antagonist. *Int J Radiat Biol* 58: 733-743.
8. Vergroesen PA, Kingma I, Emanuel KS, Hoogendoorn RJW, Welting TJ, et al. (2015) Mechanics and biology in intervertebral disc degeneration: a vicious circle. *Osteoarthritis Cartilage* 23: 1057-1070.
9. Vazquez B, Avila G, Segura D, Escalante B (1996) Anti-inflammatory activity of extracts from Aloe Vera gel. *J Ethno Pharmacol* 55: 69-75.
10. Shahzad MN, Ahmed N (2013) Effectiveness of Aloe Vera gel compared with 1% Silver Sulphadiazine cream as a burn wound dressing in second-degree burns. *J Pak Med Assoc* 63: 225-230.
11. Teplicki E, Ma Q, Castillo DE, Zarei M, Hustad AP, et al. (2018) The effects of Aloe Vera on wound healing in cell proliferation, migration, and viability. *Wounds* 30: 263-268.
12. Li W, Liu T, Wu L, Chen C, Jia Z, et al. (2014) Blocking the function of inflammatory cytokines and mediators by using IL-10 and TGF- β : potential biological immunotherapy for intervertebral disc degeneration in a beagle model. *Int J Mol Sci* 30: 263-268.
13. Davis RH, Leitner MG, Russo JM, Byrne ME (1989) Wound healing, oral and topical activity of Aloe Vera. *J of the Amer Paediatric Med Assoc* 79: 559-562.
14. Dagne E, Bisrat D, Viljoen A, Van Wyk BE (2000) Chemistry of Aloe species. *Curr Org Chem* 4: 1055-1078.
15. Hutter JA, Salman M, Stavinoha WB, Satsangi N, Williams RF, et al. (1996) Antiinflammatory C-glucosyl chromone from Aloe barbadensis. *J Nat Prod* 59: 541-543.
16. Roberts S, Hollander AP, Caterson B, Menage J, Richardson JB (2001) Matrix turnover in human cartilage repair tissue in

- autologous chondrocyte implantation. *Arthritis Rheum* 44: 2586-2598.
17. Sato Y, Ohta S, Shinoda M (1990) Studies on chemical protectors against radiation XXXI: Protective effects of *Aloe arborescens* on skin injury induced by x-irradiation. *Yakugaku Zasshi* 110: 876-884.
 18. Chithra P, Sajithlal G, Chandrakasan G (1998) Influence of *Aloe Vera* on the glycosaminoglycans in the matrix of healing dermal wounds in rats. *J Ethno Pharmacol* 59: 179-186.
 19. Hoyland JA, Maitre CL, Freemont AJ (2008) Investigation of the role of IL-1 and TNF in matrix degradation in the intervertebral disc. *J Rheumatol* 47: 809-814.
 20. Ro JY, Lee B, Kim JY, Chung Y, Chung MH, et al. (2000) Inhibitory mechanism of aloe single component (Alprogen) on mediator release in guinea pig lung mast cells activated with specific antigen-antibody reactions. *J Pharmacol Exp Ther* 292: 114-121.