

Expectant Management of Cesarean Scar Ectopic Pregnancy: A Case Report

Timothy I^{1*} and
Charles P. Mirable²

Abstract

Cesarean scar pregnancy (CSP) is a very rare form of ectopic pregnancy. It complicates approximately 1 in 2226 pregnancies. However, it is becoming increasingly more frequent with the increasing number of cesarean sections performed each year. The recommended approach to treatment is therapeutic termination of pregnancy at the time of recognition. Couples occasionally make the choice to continue with expectant management. There are as few as ten documented cases of CSP and were expectantly managed that resulted in the delivery of a viable neonate. In this article, we present a case of CSP managed expectantly ending in emergency cesarean delivery at 27 weeks gestation. Delivery was complicated by severe postpartum hemorrhage with the need for cesarean hysterectomy. This report suggests the ability to expectantly manage appropriate cesarean scar ectopic pregnancies. However, it also raises several ethical questions whether or not we should manage these patients expectantly merely because we can.

Keywords: Cesarean scar pregnancy; Ectopic pregnancy; Expectant management

Received: November 26, 2019; **Accepted:** February 05, 2020; **Published:** February 12, 2020

Introduction

Ectopic pregnancy itself complicates approximately 2% of all pregnancies [1-4]. Risk factors for ectopic pregnancy include a history of ectopic pregnancy, tubal surgery, tubal pathology, previous tubal ligation, history of sexually transmitted infections and women with intrauterine contraceptive devices in place [3]. The most common place for an ectopic pregnancy is within the ampulla of the fallopian tube. However, ectopic pregnancies can occur in several other anatomic locations including the adenexa, cervix, myometrium, cesarean scar and abdomen. In this case report, we will examine a case of cesarean scar pregnancy. Little is currently known about the risk factors for cesarean scar pregnancies. Proposed risk factors include number of previous cesarean deliveries, type of hysterotomy closure and indication for cesarean delivery, among many others. The current standard of care for cesarean scar ectopic pregnancy currently is therapeutic termination. Termination can be performed via several different routes. Each with their own set of potential complications. But, are these risks of termination absolutely necessary? Is there a possibility to expectantly manage these pregnancies? This case report will review a cesarean scar pregnancy managed expectantly.

- 1 SSM Health St. Anthony Hospital, North Lee Avenue Oklahoma City, Oklahoma, USA
- 2 The Perinatal Center of Oklahoma, West Memorial Road, Oklahoma City, Oklahoma, USA

*Corresponding author: Timothy Immonen

✉ timothy.immonen@ssmhealth.com

SSM Health St. Anthony Hospital 1000
North Lee Avenue Oklahoma City, Oklahoma
73102, USA.

Tel: 14054069386

Citation: Timothy I, Mirable CP (2020) Expectant Management of Cesarean Scar Ectopic Pregnancy: A Case Report. Gynecol Obstet Case Rep Vol.6 No.1:3

Case Report

The patient is a 32-year-old Gravida 5 Para 222 female who presented to her primary obstetrician due to positive home pregnancy test and vaginal bleeding. Her medical history is complicated by a history of red cell alloimmunization with anti-E antibodies and Factor V Leiden Heterozygote. Neither child has needed a transfusion for anti-E antibodies, and she has never had a blood clot as a result of Factor V Leiden Deficiency. The patient's reported last menstrual period was April 6th, 2018. Ultrasound dating at that visit was consistent with her last menstrual period and placed her at 7 weeks and 4 days gestation. Ultrasound identified fetal cardiac activity at 143 beats per minute, a bleed superior to the gestational sac that measures 23 × 12 × 23 millimeters in a diameter and implantation near the lower uterine segment near the cesarean scar.

Management and Outcome

Referral to Maternal Fetal Medicine for subsequent evaluation two days later was arranged due to suspicion for cesarean scar ectopic pregnancy. At this time, vaginal bleeding had resolved and

the patient had begun prophylactic Aspirin for Factor V Leiden deficiency in anticipation of normal intrauterine pregnancy. Ultrasound evaluation of the fetus was again performed with findings in **Figure 1**. Imaging was consistent with cesarean scar ectopic pregnancy. The patient was extensively counseled about the standard of care for treatment of cesarean scar ectopic pregnancy. Evaluation with Magnetic Resonance Imaging or surgical evaluation with laparoscopy was both offered. The patient declined both options. She was also counseled about therapeutic treatment options including surgical wedge resection and systemic versus local methotrexate administration. The patient was adamant about expectant management. She was counseled that if she continued with expectant management, she ran the risk of developing morbidly adherent placental complications and the potential need for hysterectomy if bleeding became life threatening. Close follow-up with Maternal Fetal Medicine was arranged with serial ultrasonographic examinations.

One week later, the patient returned to the Maternal Fetal Medicine specialist for repeat ultrasonographic evaluation. Images from this appointment are shown in **Figure 2**. It was now apparent that the patient likely had a Grade I cesarean scar ectopic pregnancy based on the myometrial invasion of the gestational sac. Fetal growth remained appropriate for gestational age. The patient was noted to have at minimum placenta accreted and was counseled ad nauseum about the potential for placenta increta/percreta if she elected to continue her pregnancy. She was again warned of the possibility of uterine rupture and the need for a hysterectomy for significant bleeding. The need for peri-viable or preterm delivery was discussed with the patient if severe hemorrhage were to develop. All thromboprophylaxis was discontinued at this visit due to potential risk of life-threatening hemorrhage. Appropriate follow-up was initiated, and all return precautions were discussed in detail.

At the next ultrasonographic evaluation, the fetus continued to have fetal heart tones and appropriate fetal growth. Imaging is shown in **Figure 3**. Corticosteroids were discussed and recommended at the cusp of viability. Continued expectant management was requested. At 12 weeks' gestation, the patient had a second opinion consultation visit with another Maternal Fetal Medicine provider who reiterated the standard of care and possible outcomes with expectant management of cesarean scar ectopic pregnancy. Images at 13 weeks' gestation are shown in **Figure 4**.

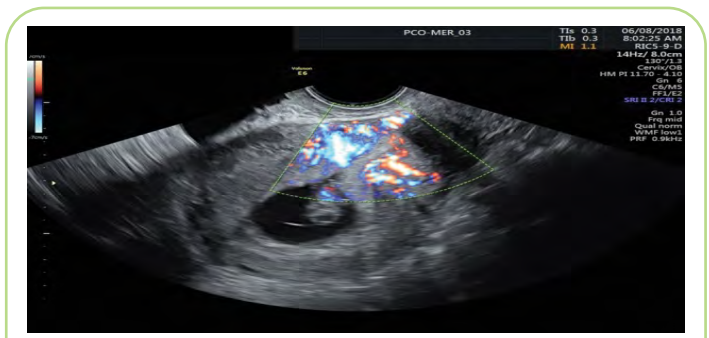


Figure 2 Placentation within cesarean scar adjacent to bladder.

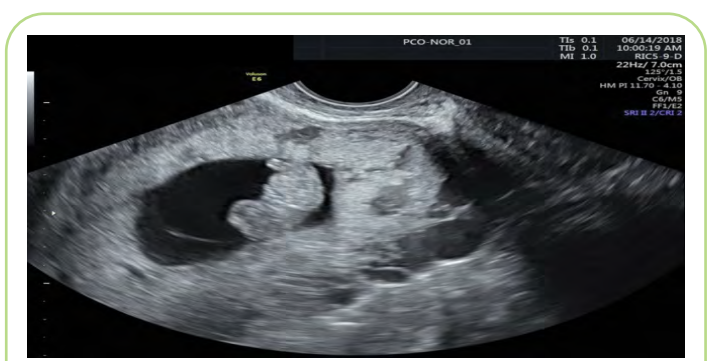


Figure 3 Ultrasonographic evaluations, the fetus continued to have fetal heart tones and appropriate fetal growth.

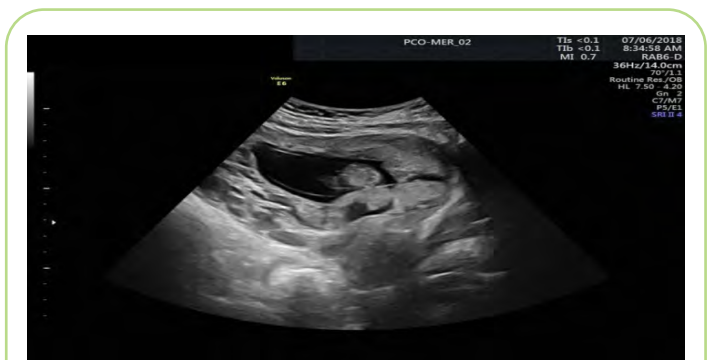

Figure 4 Large placenta lakes and continued placenta previa.

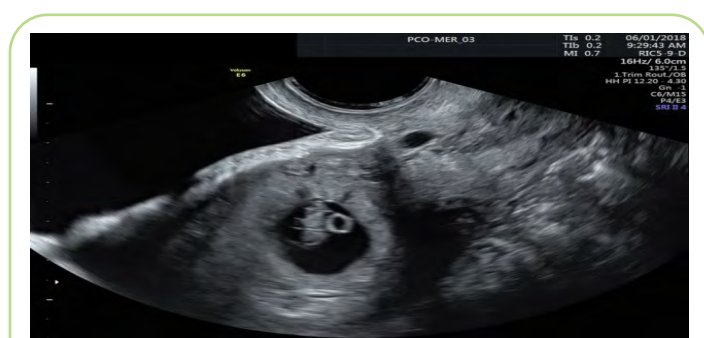


Figure 1 Shows implantation site in the lower uterine segment, consistent with cesarean scar ectopic pregnancy.

There is concern that the placental tissue has invaded to the level of the uterine serosa without penetration through the serosa and some placental tissue within the cervix. Counseling about the guarded prognosis of this pregnancy was again provided and expectant management was continued. MRI was performed and was consistent with cesarean scar ectopic pregnancy and complete placenta previa. A normal anatomy scan was performed at 16 weeks' gestation and is shown in **Figure 5**. The patient then transferred care to a provider with access to a 24-hour accerta team. Scans were readjusted to four-week intervals with strict precautions to present to the obstetrical triage unit if any bleeding persists. Placenta increta was diagnosed at an ultrasonographic evaluation at 22 weeks' gestation. Steroids were administered at 24 weeks to help accelerate fetal lung maturity. The patient presented to the obstetrical triage unit at 25 weeks and 6 days

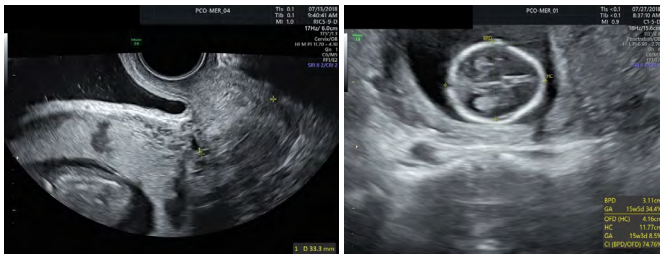


Figure 5 Definite placenta accreta with placenta previa and concern for placenta increta and fetal growth ultrasound within normal limits with a fetus measuring in the thirty-fourth percentile for gestational age.

gestation for vaginal bleeding and was admitted for observation. No active bleeding was noted, fetal heart tones were category I and she was discharged after overnight monitoring.

She represented to the obstetrical triage unit at 27 weeks and 4 days gestation, again for vaginal bleeding. Bleeding was heavier, yet still minimal. However, fetal heart tones were noted to be category II and unresolved with maternal resuscitative measures; therefore, a decision was made to move forward with cesarean hysterectomy. The Maternal Fetal Medicine team performed the cesarean section. Skin incision was vertical and midline. Classical cesarean section was performed with a transverse fundal incision. Neonate was delivered without difficulty with APGARs of 2/6/8 at 1, 5 and 10 minutes respectively. The fetus weight was 780g at time of delivery. Complete placenta previa with invasion into the lower uterine segment was identified. The placenta was left *in situ* and the hysterotomy was whip stitched closed. Blood loss at completion of the cesarean section was 4000 milliliters. After closure of the hysterotomy, the Gynecologic Oncology team began the hysterectomy portion of the procedure. The hysterectomy was performed in the standard fashion. Blood loss during the hysterectomy was noted to be an additional 1500 milliliters for a total blood loss of 5500 milliliters. The patient received five units of packed red blood cells, five units of fresh frozen plasma and one unit of platelets. The fascia was reapproximated with PDS suture. The subcutaneous tissue was reapproximated with 3-0 vicryl suture. The skin was reapproximated with 4-0 monocryl suture. Dermabond was placed over the incision. The patient was unable to be extubated and was transferred to the Intensive Care Unit for close monitoring.

She was extubated on the day of surgery. On post-operative day number one, she was transferred back to labor and delivery. Hemoglobin was stable at 10.3 and she was noted to be hemodynamically stable. She was meeting all post-operative goals by post-operative day number four. Pathologic examination of the uterus reveals a relatively normal appearing cervix that is completely covered by the placenta. The myometrium averages 3.0 centimeters in thickness. The endometrium is approximately 0.2 centimeters in thickness. The placenta comprises the entire lower uterine segment without serosal penetration. The placenta contains a sub-amniotic hemorrhage near the umbilical cord insertion site. The fallopian tubes were grossly normal in appearance.

Discussion

The actual incidence of cesarean scar pregnancies is unknown as there are few documented cases. One study report that cesarean scar ectopic pregnancy complicates 1 in 2226 pregnancies [1]. Several studies have been conducted to potentially identify potential risk factors for cesarean scar pregnancy. Studies have shown that the risk for cesarean scar pregnancy does not correlate to the number of previous cesarean deliveries [5]. Some had proposed that the method of closure may impact the likelihood of cesarean scar pregnancy; however, there is no evidence that supports double versus single layer closure of the uterus helps prevent cesarean scar pregnancy. It does appear that cesarean section performed on an unlabored lower uterine segment may interrupt proper healing, thus, leading to slightly increased risk of cesarean scar pregnancy [6]. With the increasing number of cesarean sections being performed around the world, the incidence is likely to increase over the next several generations.

Cesarean scar ectopic pregnancy is classified into one of three sub-groups based on ultrasonographic features at the time of diagnosis, each with its own prognosis. The classification system is shown in **Figure 6** [2]. Classification is based on the location of the gestational sac and the amount of myometrium remaining. Grade I is defined as the gestational sac penetrating less than half of the myometrium. In grade II cesarean scar ectopic pregnancies, the gestational sac penetrates greater than half the myometrium. In grade III cesarean scar ectopic pregnancies, the gestational sac extends outside the myometrium. Finally, in grade IV cesarean

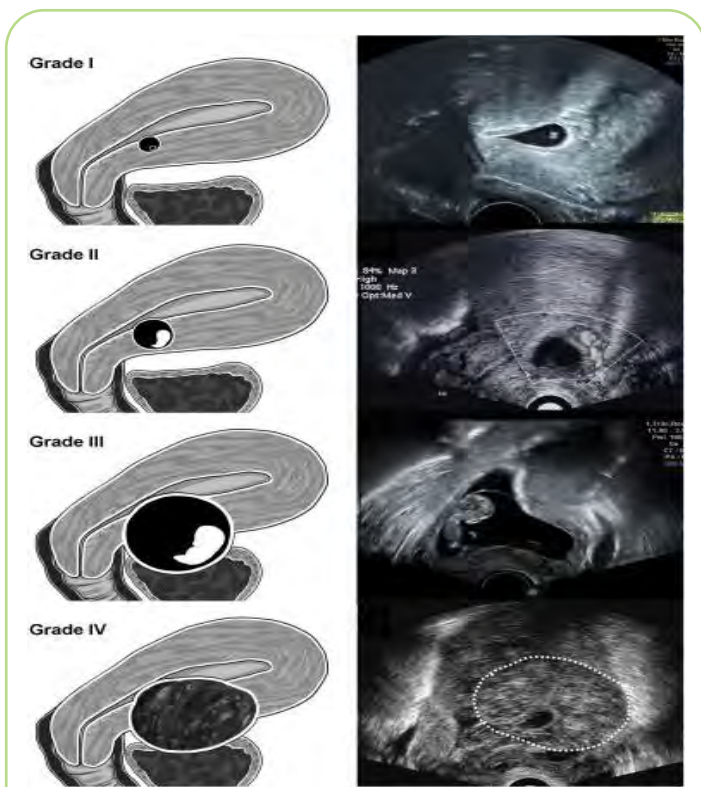


Figure 6 Cesarean scar ectopic pregnancy classification system.

scar ectopic pregnancies, the gestational sac is highly vascular, and the pregnancy is difficult to identify.

The standard of care for cesarean scar ectopic pregnancy currently is therapeutic termination. There are several routes of termination that have been discussed; no one method proves to be superior to the others. As with many diagnoses there are medical, surgical and expectant management options. Medical management is performed with systemic methotrexate, intragestational methotrexate or intragestational potassium chloride. The dosage for both systemic and intragestational methotrexate is 50 mg/m². A study performed by Kim et al. showed significantly better results with intragestational methotrexate when compared to systemic methotrexate [7-11]. Approximately 93% of cesarean scar pregnancies treated with intragestational methotrexate had complete resolution versus 73% with systemic methotrexate [11]. Medical management alone has been associated with the need for further surgical intervention with b-HCG greater than 6,000 mIU/mL via dilation and curettage or uterine artery embolization [5]. Several surgical interventions have been reported for the treatment of cesarean scar ectopic pregnancy. Surgical intervention leads to a more rapid decline in b-HCG levels than medical management. Surgical procedures for management of cesarean scar ectopic pregnancy include dilation and curettage, hysteroscopic resection, and laparoscopic versus open wedge resection. Dilation and curettage alone is often complicated by hemorrhage with up to 76% requiring a second intervention and 14% requiring hysterectomy [5]. Hysteroscopic resection is completed with a 30 degree hysteroscope using cold resection techniques. Resection of products of conception is completed intact or piecemeal until the myometrium is able to be visualized [12]. Any residual bleeding is then cauterized with electrocautery or balloon tamponade with a foley catheter balloon. Laparoscopic removal of cesarean scar pregnancy involves identification of the cesarean scar. Once identified the scar is incised with monopolar cautery and the gestational sac is removed through one of the trochar sites. The remaining cesarean scar is then removed with monopolar cautery and the defect is repaired in a two layer closure [12]. Hysteroscopic and

laparoscopic resection is not recommended for patients with less than three millimeters of myometrium remaining due to risk of bladder injury [7]. Laparoscopic and open wedge resection provides the opportunity to repair the lower uterine segment and theoretically reduce the risk for recurrence [8]. Laparotomy is specifically indicated for patients with suspected uterine rupture and hemodynamic instability. Hysterectomy is often indicated if bleeding is unable to be controlled via laparotomy [9]. Very few women have elected for expectant management. In one study, 10 patients elected for expectant management. Of those, four patients delivered viable neonates (40%) and three of those women required hysterectomy at time of delivery (75%) [10-12].

Conclusion

This case report summarizes expectant management of a rare, cesarean scar ectopic pregnancy. A pregnancy outcome that complicates roughly 1 in 2226 pregnancies. The patients choose this treatment plan and successfully delivered a viable, although very preterm, infant. She overcame the odds as it is documented that approximately only 40% of expectantly managed cesarean scar ectopic pregnancies will go on to deliver viable neonates. Like many of her cohort, she also underwent cesarean hysterectomy as part of her treatment. It can be concluded, based on the grade of cesarean scar ectopic pregnancy, some patients may be a candidate for expectant management with appropriate counseling. Appropriate counseling would include that of mass hemorrhage, possible invasive placentation, cystectomy, possible need for cystostomy tube placement and need for cesarean hysterectomy. Counseling regarding when to present to the obstetrical triage unit for evaluation is of utmost importance; however, in the end, delivering a viable neonate is a possibility for women with cesarean scar ectopic pregnancy. The real questions comes in the form of medical ethics, specifically, non-maleficence. Just because we have the capability and the means to successful deliver a pregnancy such as the one presented in the case should we "recommend" it? Should we tell a woman to carry these pregnancies knowing the potential risks discussed above?.

References

- 1 Ash A, Smith A, Maxwell D (2007) Cesarean scar pregnancy. *BJOG: Intl J Obstet Gynaecol* 114: 253-263.
- 2 Lin SY, Hsieh CJ, Tu YA, Li YP, Lee CN, et al. (2018) New ultrasound grading system for cesarean scar pregnancy and its implications for management strategies: An observational cohort study. *PLoS One* 13(8): e0202020.
- 3 Jurkovic D, Wilkinson H (2011) Diagnosis and management of ectopic pregnancy. *BMJ* 342: 3397.
- 4 ACOG Committee (2018) Practice Bulletins Tubal ectopic pregnancy: ACOG practice bulletin Clinical Management Guidelines. *Obstet Gynecol* 131 (3): e91-e103.
- 5 Rotas MA, Haberman S, Levгур M (2006) Cesarean scar ectopic pregnancies: Etiology, diagnosis, and management. *Obstet Gynecol* 107: 1373-1381.
- 6 Maymon R, Halperin R, Mendlovic S, Schneider D, Herman A (2004) Ectopic pregnancies in a caesarean scar: review of the medical approach to an iatrogenic complication. *Hum Reprod Update* 10: 515-523.
- 7 Marotta ML, Donnez J, Squifflet J, Jadoul P, Darii N, et al. (2013) Laparoscopic repair of post-caesarean section uterine scar defects diagnosed in nonpregnant women. *J Minim Invasive Gynecol.* 20: 386-391.
- 8 Siedhoff MT, Schiff LD, Moulder JK, Toubia T, Ivester T (2015) Robotic-assisted laparoscopic removal of cesarean scar ectopic and hysterotomy revision. *Am J Obstet Gynecol* 212: 681.
- 9 Fylstra DL (2002) Ectopic pregnancy within a cesarean scar: A review. *Obstet Gynecol Surv* 57: 537-43.
- 10 Timor-Tritsch IE, Khatib N, Monteagudo A, Ramos J, Berg R, et al. (2015) Cesarean scar pregnancies: An experience of 60 cases. *J Ultrasound Med* 34: 601-610.

- 11 Kim YR, Moon MJ (2018) Ultrasound-guided local injection of methotrexate and systemic intramuscular methotrexate in the treatment of cesarean scar pregnancy. *Obstet Gynecol Sci* 61(1): 147-153.
- 12 Pirtea L, Balint O, Secosan C, Grigoras D, Ilinca R (2019) Laparoscopic resection of cesarean scar ectopic pregnancy after unsuccessful systemic methotrexate treatment. *Journal of Minimally Invasive Gynecology* 26(3): 399-400.