

DOI: 10.21767/2575-7733.100033

Endoscopic Resection of an Inflammatory Fibroid Polyp in the Cecum: A Case Report

Kentaro Yazawa*, Yuki Azuma, Tomohiro Kurokawa, Yuichiro Yoshioka, Giichiro Tsurita and Masaru Shinozaki

Department of Surgery, IMSUT Hospital, The Institute of Medical Science, The University of Tokyo, Tokyo, Japan

*Corresponding author: Kentaro Yazawa, Department of Surgery, IMSUT Hospital, The Institute of Medical Science, The University of Tokyo, Tokyo, Japan, Tel: +8190-9345-2991; E-mail: yazawa@ims.u-tokyo.ac.jp

Rec date: February 07, 2018; Acc date: February 19, 2018; Pub date: February 23, 2018

Citation: Yazawa K, Azuma Y, Tomohiro K, Yoshioka Y, Tsurita G, et al. (2018) Endoscopic Resection of an Inflammatory Fibroid Polyp in the Cecum: A Case Report. J Clin Gastroenterol Hepatol Vol.2: No.1:4.

Abstract

Introduction: Inflammatory fibroid polyps (IFPs) are rare, benign lesions of the gastrointestinal tract. Their occurrence in the colon is rare. They are often surgically resected for various reasons.

Case presentation: A 60-year-old woman presented to our institution. She had a history of gynecologic surgery for cervical cancer at 37 years of age. Colonoscopy was performed by a local doctor and a type I tumor on Bauhin's valve was suspected. Colonoscopy performed by us revealed a pedunculated polypoid tumor with a 20-mm head that was found to have a long stalk in the cecum. It was inferred that the stalk was entering and exiting through the valve since submucosal bleeding was observed. Polypectomy was performed. The histopathological diagnosis was IFP. Colonoscopy performed after 6 months showed no polyp recurrence.

Discussion: According to previous reports, the treatment of colonic IFP was surgical in 58% of cases and endoscopic resection was performed in only 23% of cases. The decision to perform surgery was based on various factors, such as polyp size and position, difficulty in diagnosis by biopsy, and patient symptoms. In the present case, we could successfully perform polypectomy before the appearance of symptoms. Endoscopic resection seems to be an appropriate treatment approach due to the benign nature of IFP. The etiology of IFP remains unknown.

Conclusion: The decision to perform surgery or endoscopic resection should be done on a case-by-case basis, but we think that a favorable increase in the number of endoscopic resections will occur in the future.

Keywords: Inflammatory fibroid polyp; Submucosal tumor of the colon; Pedunculated polypoid tumor; The polyp's head was entrapped in Bauhin's valve; Endoscopic resection

Introduction

Inflammatory fibroid polyps (IFPs) are rare, benign lesions that arise in the submucosa of the gastrointestinal tract. These lesions occur most commonly in the stomach, less frequently in the ileum, and rarely in the colon [1-4]. In many cases, it is necessary to perform lesion resections by surgery due to the size of the lesion [3], the difficulty of establishing a definitive diagnosis by biopsy [4], and urgency due to symptoms. We report a case of an endoscopically resected cecal IFP that was incidentally discovered in an asymptomatic patient.

Case Presentation

The patient is a 60-year-old woman. She had a history of surgery, expansion simple hysterectomy, and resection of a right ovarian cyst due to cervical cancer (SCC *in situ*, Stage 0). She was followed up for 15 years after surgery, during which period no recurrence was noted.

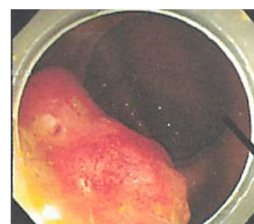

Figure 1 The colonoscopy photograph attached with the introduction letter. It was written that there was a type I tumor on Bauhin's valve. It appears to be the case.

Colonoscopy was performed by a local doctor for medical examination and a type I tumor on Bauhin's valve was suspected and the patient was referred to our hospital. According to the photograph that accompanied the referral

letter, the lesion appeared to be a type I tumor, and colon cancer was strongly suspected (**Figure 1**).

The patient was hospitalized for further examination. She had no spontaneous symptoms upon examination and abdominal findings only showed a surgical scar in the lower abdomen. No remarkable findings were observed through hematological tests. No tumor was detected during the colonoscopy that we performed and as seen in the photograph accompanying the referral letter. In addition, a pedunculated polypoid tumor with a 20-mm head was found with a long stalk in the cecum, and was in contact with the lower lip of Bauhin's valve (**Figure 2**).

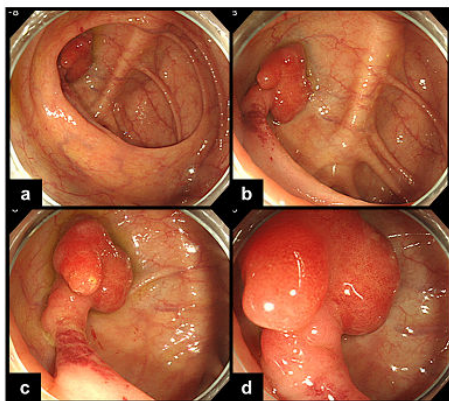


Figure 2 In the colonoscopy that we performed, a pedunculated polypoid tumor of about 20-mm head was found having a long stalk in the cecum in contact with the lower lip of Bauhin's valve (a-c). Submucosal bleeding was predominantly found in the stalk of the polyp (c). The polyp was irregularly shaped and relatively smooth on the surface, and a saccular-like erosion was seen in the head, with the so-called glans penis appearance (d).

The polyp was irregularly shaped and its surface was relatively smooth. A saccular-like erosion was seen on the head, which exhibited the so-called glans penis appearance (**Figure 2**). No abnormality was found at the terminal ileum. Submucosal bleeding was predominantly found in the polyp stalk (**Figure 2**), and it was inferred that the stalk was repeatedly entering and exiting from Bauhin's valve to the terminal ileum (**Figure 3**).

Since the polyp's head was entrapped in Bauhin's valve, the referring doctor thought that it was a type I tumor. Early colorectal cancer was suspected to some extent, and endoscopic resection was considered to be easy. Therefore, we decided to perform endoscopic resection, for both treatment and diagnosis. After taking a detachable snare at the root of the stalk, polypectomy was performed (**Figure 4**).

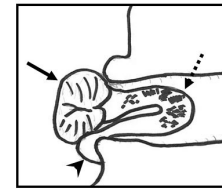


Figure 3 Expected figure that polyp is entrapped in Bauhin's valve. The referring doctor diagnosed the patient with a type I tumor based on this observation. The solid line arrow indicates the polyp head, the dotted line arrow indicates the stalk, and the arrowhead indicates the lower lip of Bauhin's valve.

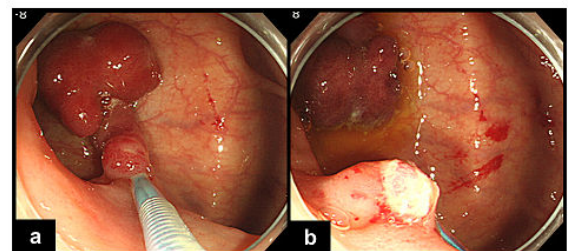


Figure 4 Endoscopic resection of the cecal IFP. After taking a detachable snare at the root of the stalk (a), the snare polypectomy was performed (b).

The patient was discharged the next day. Characteristic findings were observed on histopathological examination (**Figure 5**).

Thus, we diagnosed the patient as having an inflammatory fibroid polyp (IFP). IgG4 and c-kit yielded negative results by immunostaining. In particular, no findings were indicative of the presence of malignancy. We performed a repeat colonoscopy after 6 months and found scarring on the polypectomy site on the lower lip of Bauhin's valve. No other abnormal findings were found.

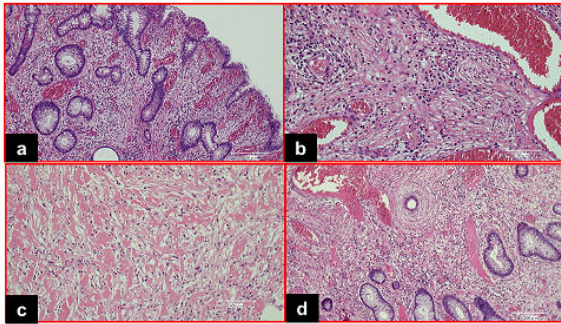


Figure 5 Histological examination (hematoxylin and eosin staining) of the pedunculated polypoid lesion in the cecum established the diagnosis of IFP. Characteristic findings such as capillary hyperplasia of mucosal lamina propria and submucosa (a), infiltration of inflammatory cells including eosinophils (b), increase of collagen fibers (c), fibrillar connective tissue which is concentrically arranged around blood vessels (d), were observed.

Discussion

IFPs were first described in 1920 by Konjetzny [5] as smooth, usually solitary, submucosal proliferating growths with inflammatory eosinophilic and fibroblastic infiltration. Endoscopically, IFP is a smooth sessile or pedunculated polyp. Histologically, IFP reveals cellular proliferation likely originating from the submucosa and has specific features, such as various-sized blood vessels in the stroma of the lesion; fibrous connective tissue consisting of spindle-shaped cells around the blood vessels (onion skin appearance); and nonspecific inflammatory cell infiltration, especially eosinophils [6]. IFP is mostly found in the stomach (70%) and the small intestines (20%). Colonic IFP is rare and most commonly located in the proximal colon, especially in the cecum [1]. Kayyali et al. [7] summarized 31 cases of colonic IFP. According to the report, the polyp size ranged between 0.5-7 cm, with a median diameter of 3.8 cm, and 44% were pedunculated while 20% were sessile. Treatment approach was surgical in 58% while endoscopic resection was performed in only 23%. There was no reported recurrence in the colon. Surgical resection is the most common method of treatment for large colonic IFP. The clinical presentation of IFP generally depends on size and location. In many cases, they can cause abdominal pain, hematochezia, anemia, weight loss, diarrhea, and intussusceptions [8], although there are a few cases without symptoms. There are many cases of emergency surgery, and it can be considered that surgical resections were the only choice. Furthermore, biopsy often can be challenging because the epicenter of the lesion is in the submucosa and the polyp is often covered by epithelial mucosa. It is natural to choose surgical resection if endoscopic resection is complicated and if there is a possibility of malignancy.

Fortunately, the polyps in the present case were pedunculated and had a size of 20 mm, which was adequate for endoscopic resection. There was a report [9] that stated that resection by endoscopic polypectomy for pedunculated-type IFP is usually difficult because the stalk of the polyp is generally stiff. In our case, however, we were able to perform the polypectomy smoothly by taking a detachable snare at the root of the stalk. Furthermore, there was a possibility that the polyp became entrapped in Bauhin's valve and caused an ileus, but it was also fortunate that we could perform polypectomy before symptoms appeared. Endoscopic resection of colonic IFP is thought to be an appropriate approach if possible, although we know that our case is rare because of favorable conditions, which were mainly due to the benign nature of IFP and its low recurrence rate [10].

The etiology of IFP remains unknown. Some authors have proposed that IFP is caused by an allergic reaction to an inflammatory stimulus, such as bacteria, chemicals, and trauma, or that it is a reactive lesion, which is fibroblastic or myofibroblastic in nature.

There is no report an IFP has metastasis and is only one case of polyp recurrence [11]. However, some complications can develop due to the sheer size of the tumor (e.g. intussusceptions). Therefore, currently, our recommendation is resection, counselling about the possibility of recurrence and repeat screening endoscopies. Recently, there were reports of familial occurrence and recognition of activating platelet-derived growth factor receptor alpha (PDGFRA) mutations in these tumors. These reports suggest that IFPs represent true neoplasms [12]. However, PDGFRA mutations have been not found in a lot of IFPs. It is thought that the clarification of the pathology will be promoted by accumulation of these various types of further cases [13,14].

Conclusion

We presented the rare case of a cecal IFP, which was easily endoscopically resected, although colonic IFP is predominantly treated with surgical resection. Whether surgery or endoscopic resection should be decided by considering each case, but we think the number of endoscopic resections will increase in the future because IFP is benign, and it reduces the burden on the patient.

References

1. John stone JM, Morson BC (1978) Inflammatory fibroid polyp of the gastrointestinal tract. *Histopathology* 2: 349-361.
2. Shimer GR, Helwig EB (1984) Inflammatory fibroid polyps of the intestine. *Am J Clin Pathol* 81: 708-14.
3. Nakase H, Mimura J, Kawasaki T, Itani T, Komori H, et al. (2000) Endoscopic resection of small inflammatory fibroid polyp of the colon. *Intern Med* 39: 25-27.
4. Ozolek JA, Sasatomi E, Swalsky PA, Rao U, Krasinskas A, et al. (2004) Inflammatory fibroid polyps of the gastrointestinal tract: clinical, pathologic, and molecular characteristics. *Appl Immunohistochem Molecul Morphol* 12: 59-66.

5. Konjetzny GE (1920) Uber magenfibrome. Beitr Klin Chir 119: 53-61.
6. Helwig EB, Ranier A (1953) Inflammatory fibroid polyps of the stomach. Surg Gynecol Obstet 96: 355-367.
7. Kayyali A, Toumeh A, Ahmad U, De Las Casas LE, Nawras A (2013) Giant inflammatory fibroid polyp of the descending colon treated with endoscopic resection. ACG Case Rep J 1: 36-39.
8. Lifschitz O, Lew S, Witz M, Reiss R, Griffel B (1979) Inflammatory fibroid polyp of sigmoid colon. Dis Colon Rectum 22: 575-577.
9. Ihimoyan A, Chelimilla H, Balar B (2012) An inflammatory fibroid polyp in the hepatic flexure of the colon treated with argon plasma coagulation, endoscopic clipping and polypectomy. Case Rep Gastroenterol 6: 63-68.
10. Goldman EL, Friedman NB (1967) Neurogenic nature of so-called inflammatory fibroid polyps of the stomach. Cancer 20: 134-143.
11. Akbulut S (2012) Intussusception due to inflammatory Fibroid polyp: a case report and comprehensive literature review. World J Gastroenterol 18: 5745-5752.
12. Siminas S, Qasem E, Shukla R, Turnock R (2014) Inflammatory fibroid polyp: a rare benign tumor of the alimentary tract in children presenting as intussusception-case report and review of literature. European J Pediatr Surg Rep 2: 16-19.
13. Zhao Y, Fu YW, Wang WC, Ting L (2017) A case of inflammatory fibroid polyp with an elongated shape in cecum. Chin Med J 130: 2130-2131.
14. Adams HS, Bergstrom B, Haines B, Roberts N (2017) Inflammatory fibroid polyp: An unusual cause of ileoileal intussusception. Case Reports in Surgery 2017.