

CASE REPORT

Ectopic Pancreas Presenting as Periapillary Tumor with Obstructive Jaundice and Pruritus Is a Rare Diagnostic and Therapeutic Dilemma. A Case Report

Ram Nawal Rao, Yadav Kamlesh, Gupta Pallav, Nidhi Singla

Department of Pathology, Sanjay Gandhi Postgraduate Institute of Medical Sciences.
Lucknow, UP, India

ABSTRACT

Context Ectopic pancreatic rest is an uncommon condition resulting in diverse clinical and pathological presentation. It results from altered development of two primitive pancreatic buds that fuse to form the uncinata-head and body-tail of normal gland. Ectopic pancreas is an anomaly where an ectopic rest develops at a place away from the normal site. **Case report** We describe a 48-year-old male patient who presented with progressive jaundice and pruritus. He was established to have a periapillary mass highly suggestive of malignancy, for which he undergo pancreaticoduodenectomy. However, histology showed ectopic pancreatic tissue in the periapillary region. **Conclusion** This case highlights importance of preoperative histological diagnosis of periapillary tumors to avoid morbid surgical procedure in the form pancreaticoduodenectomy. Ectopic pancreas should include differential diagnosis of periapillary tumors.

INTRODUCTION

Ectopic pancreas is comparatively rare developmental abnormality, which can be noted both during operations and post-mortem autopsies. It usually occurs in the upper gastrointestinal tract, the commonest sites being duodenum (27.5%), stomach (25-35%) and jejunum (15.9%) [1]. We report a patient presenting with symptoms of ampillary tumor with obstructive jaundice and pruritus, but the radiological imaging study did not suggest the possibility of ectopic pancreas preoperatively. Clinically, ectopic pancreas is identified with an expected frequency of one in every 500 upper abdominal operations [2]. Less than 25 cases of ectopic pancreas at periapillary region have been reported so far in the literature [3, 4, 5, 6, 7, 8, 9].

CASE REPORT

A 48-year-old male presented with progressive jaundice and pruritus for 2 months. There was no history of anorexia, GI bleeding, loss of weight or

vomiting. Patient had history of cigarette smoking since 15 years (1-2 daily) without past medical history of alcohol habits. No history of previous surgery was done. Patient had undergone magnetic cholangio-pancreatography (MRCP) followed by endoscopic retrograde cholangiopancreatography (ERCP) with stenting at a centre outside before being referred to our hospital for further one management. On physical examination patient was conscious and oriented. Patient had jaundice and on abdominal examination there was organomegaly. Peripheral lymph nodes were not palpable. Pulse rate was 80/min, regular and blood pressure was 110/70 mmHg. Other vital systems were within normal limits.

On investigation routine hemogram was normal and serum biochemical analysis showed raised serum total bilirubin with predominance of conjugated fraction (6.5 mg/dL; reference range: 0-0.4 mg/dL). CA 19-9 was within normal range (2.36 U/mL; reference range: 1.2-30.9 U/mL). Ultrasound abdomen showed mild thickening and edema in gallbladder wall. Rest of the abdominal organs was normal. Contrast enhanced computed tomography (CECT) showed no focal lesion in liver; however, mild intrahepatic biliary radicle dilatation with pneumobilia was noted. Common bile duct stent in situ was seen and proximal common bile duct was dilated. Gallbladder wall was thickened and edematous. Subcentimeter lymph nodes were seen at porta and around celiac axis. MRCP showed diffuse gallbladder wall thickening with calculi. A small rounded soft tissue lesion was seen in periapillary

Received July 26th, 2011 - Accepted September 6th, 2011

Keywords Jaundice, Obstructive; Neoplasms; Pancreas

Correspondence Ram Nawal Rao

Department of Pathology; 1st Floor, New Diagnostic Block;
Sanjay Gandhi Postgraduate Institute of Medical Science;
Lucknow, UP, 226014; India

Phone: +91-0522.249.5259

Fax: + 91.0522.266.8017; +91-0522.266.8078

E-mail: rnrao@sgpgi.ac.in; rnawalrao@gmail.com

Document URL <http://www.joplink.net/prev/201111/06.html>

region and protruding into duodenal lumen. ERCP was done outside and showed smooth papilla and normal mucosa for which needle knife papillotomy and stenting was done.

On laparoscopy there was no evidence of dissemination in the form of liver metastasis, peritoneal/serosal or pelvic deposits. Ascites was not seen. Pancreas was soft and main pancreatic duct was 2.0 mm. A 1.5x1.0 cm nodular lesion was identified in the periampullary area. A single soft common hepatic artery lymph node was also seen. Staging laparoscopy and pylorus preserving pancreaticoduodenectomy was done.

Gross Feature

Pancreaticoduodenectomy specimen showed a growth measuring 1.5x1.0 cm. in the periampullary region. Cut surface showed yellow variegated solid mass (Figure 1). It was entirely separate from the native pancreas.

Histopathological Examination

Histopathological examination of the surgical specimen from periampullary nodule showed ectopic pancreatic tissue composed of ducts, acini, and well-formed islets in the mucosa and submucosa of the duodenum (Figure 2). Focal area of mucosal ulceration was seen (Figure 3). Even on extensive sampling of the specimen there was no gross or microscopic evidence of malignancy seen.

DISCUSSION

Ectopic pancreatic tissue turn out during surgical exploration is rare, accounting for less than 0.5% of laparotomy, but it is found in 13.7% of autopsies [3]. Common sites of ectopic pancreas are duodenum and gastric mucosa although theoretically it can occur anywhere in the body. Few cases have been reported in the literature as periampullary mass lesion resulting in obstructive jaundice [10, 11, 12]. Clinical presentation of our case is similar to the earlier cases which reported in literature as mimicker of periampullary carcinoma. Hammastromm *et al.* described 10 cases of ectopic pancreatic tissue in which one patient had endoscopic sphincterotomy done and the endoscopic biopsy

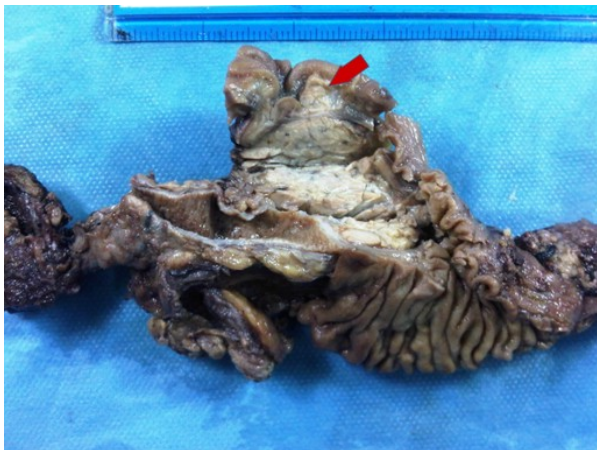

Figure 1. Pancreaticoduodenectomy specimen showed a growth measuring 1.5x1.0 cm. in the periampullary region (arrow).

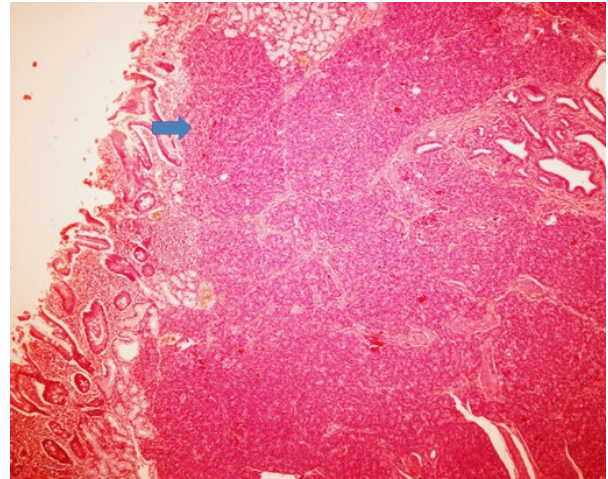


Figure 2. Histopathology section showed ectopic pancreatic tissue composed of ducts, acini, and well-formed islets in the mucosa and submucosa of the duodenum (arrow).

revealed ectopic pancreas [7]. Ectopic pancreas can mimick cholangiocarcinoma rarely [13]. Exact preoperative diagnosis of ectopic pancreas in the periampullary region using endoscopy and radiological imaging is difficult. The presence of central umbilication on endoscopy, though a characteristic finding in ectopic pancreas, is quite infrequent. Ectopic pancreas creating clinico-pathologic diagnostic dilemma resulting in Whipple procedure is reported in literature [4]. In 1859, Klob presented histological confirmation of ectopic pancreatic tissue in two cases [14].

CECT did not appear to be helpful in establishing the diagnosis of ectopic pancreas preoperatively. In our case, MRCP showed a small rounded soft tissue lesion in periampullary region and protruding into duodenal lumen. Magnetic resonance imaging or cholangio-pancreatography (MRI/MRCP) was done only in one other case [9] where it was also not helpful in making the diagnosis. Endoscopic ultrasound (EUS) may have an important role to play in the diagnosis. At EUS, ectopic pancreas in the upper gastrointestinal tract is usually hypoechoic and heterogeneous with indistinct margins and is most commonly seen to arise from the submucosa. However, EUS was performed in only one

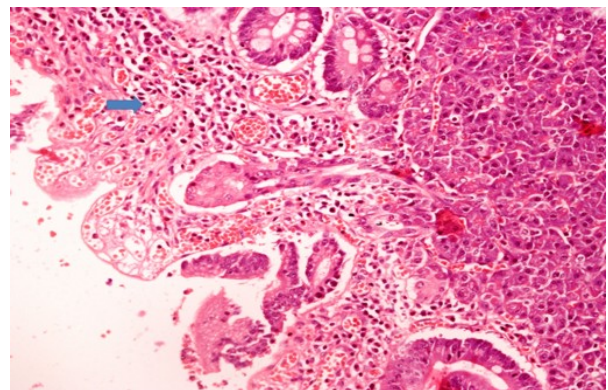


Figure 3. Section showed focal ulceration and mixed inflammation of mucosa in pariampullary region (arrow).

of the 22 patients with periampullary heterotopic pancreas in the earlier series. Although EUS suggested benign pathology, it misdiagnosed the ectopic pancreas as a leiomyoma [4].

The local excision of ectopic pancreas when sufficient, rather than radical operation, can be the treatment of choice [5]. However, given the difficulties with correct preoperative diagnosis and the suspicion of an underlying periampullary malignancy, pancreaticoduodenectomy was performed in 14 (64%) of the 22 patients. Five patients were successfully managed by local excision (three by ampullectomy and two by excision of the common bile duct). Among three patients who had ampullectomy, the benign nature of the pathology was suggested by either EUS [4] or pre-operative frozen section biopsy [6] or pre-operative endoscopic biopsy [8].

CONCLUSION

Ectopic pancreas in the periampullary region presenting as malignancy with progressive jaundice and pruritus is a rare entity and remains difficult to diagnose, despite advances in radiological and endoscopic imaging techniques. Our patient was clinically diagnosed as periampullary tumor due to ectopic pancreas highlights importance of preoperative histological diagnosis of mass in periampullary region to avoid morbid surgical procedure in the form of pancreaticoduodenectomy. Ectopic pancreas should include differential diagnosis of periampullary tumors, although rare in the lists.

Conflict of interest The authors have no potential conflicts of interest

References

1. Dolan RV, ReMine WH, Dockerty MB. The fate of heterotopic pancreatic tissue. A study of 212 cases. *Arch Surg* 1974; 109:762-5. [PMID 4420439]
2. Barbosa JC, Dockerty M, Waugh JM. Pancreatic heterotopia. Review of the literature and report of 41 authenticated surgical cases of which 25 were clinically significant. *Surg Gynecol Obstet* 1946; 82:527-42. [PMID 21024692]
3. Pearson S. Aberrant pancreas: review of the literature and report of three cases, one of which produced common and pancreatic duct obstruction. *AMA Arch Surg* 1951; 63:168-86. [PMID 14846476]
4. Chen CH, Yang CC, Yeh YH, Chou DA, Kuo CL. Ectopic pancreas located in the major duodenal papilla: case report and review. *Gastrointest Endosc* 2001; 53:121-3. [PMID 11154509]
5. Molinari M, Ong A, Farolan MJ, Helton WS, Espat NJ. Pancreatic heterotopia and other uncommon causes of non-malignant biliary obstruction. *Surg Oncol* 2000; 9:135-42. [PMID 11356342]
6. Laughlin EH, Keown ME, Jackson JE. Heterotopic pancreas obstructing the ampulla of Vater. *Arch Surg* 1983; 118:979-80. [PMID 6870529]
7. Hammarstrom LE, Nordgren H. Ectopic pancreas of the ampulla of Vater. *Endoscopy* 1999; 31:S67. [PMID 10604636]
8. Contini S, Zinicola R, Bonati L, Caruana P. Heterotopic pancreas in the ampulla of Vater. *Minerva Chir* 2003; 58:405-8. [PMID 12955065]
9. Obermaier R, Walch A, Kurtz C, von Dobschuetz E, Adam U, Neeff H, et al. Heterotopic pancreatitis with obstruction of the major duodenal papilla - A rare trigger of obstructive orthotopic pancreatitis. *Pancreatol* 2004; 4:244-8. [PMID 15148443]
10. Hsu SD, Chan DC, Hsieh HF, Chen TW, Yu JC, Chou SJ. Ectopic pancreas presenting as ampulla of Vater tumor. *Am J Surg* 2008; 195:498-500. [PMID 18304504]
11. Wagle PK, Shetty GS, Sampat M, Patel K. Ectopic pancreatic tissue mimicking ampullary tumor. *Indian J Gastroenterol* 2005; 24:265-6. [PMID 16424630]
12. Filippou DK, Vezakis A, Filippou G, Condilis N, Rizos S, Skandalakis P. A rare case of ectopic pancreas in the ampulla of Vater presented with obstructive jaundice. *Ann Ital Chir* 2006; 77:517-9. [PMID 17343237]
13. Biswas A, Ehab A Husain, Roger M Feakins, et al. Heterotopic pancreas mimicking cholangiocarcinoma. Case report and literature review. *JOP. J Pancreas (Online)* 2007; 8:28-34. [PMID 17228130]
14. Klöb J. Pancreas accessorium. *Zeitschrift der Kaiserl. Königl. Gesellschaft der Aerzte zu Wien* 1859; 15:732.