

Diabetic Retinopathy: Origin and Complications

Ankur Rohilla^{*1}, Rupesh Kumar¹, Seema Rohilla², Ashok Kushnoor¹

¹*Department of Pharmaceutical Sciences, Shri Gopi Chand Group of Institutions, Baghpat, UP, India*

²*Department of Pharmaceutical Sciences, Hindu College of Pharmacy, Sonapat, Haryana, India*

ABSTRACT

Diabetic Retinopathy (DR) is a complication of diabetes associated with irreversible loss of blindness. Various types of DR have been reported like mild non-proliferative retinopathy, moderate non-proliferative retinopathy, severe non-proliferative retinopathy and proliferative retinopathy. A number of signaling mechanisms like nuclear factor kappa-B (NF- κ B), cyclo-oxygenase (COX), intracellular adhesion molecules (ICAM-1), interleukin-1beta (IL-1 β) has been found to be implicated in the pathogenesis of diabetic retinopathy. The review article critically explains the signaling mechanisms and complications associated with DR. Moreover, the strategies to treat DR have been discussed in the present review article.

Key Words: Diabetic, retinopathy, signaling, complications.

INTRODUCTION

Diabetes has been recognized as the major health burden worldwide [1]. Diabetes is a group of metabolic disease that occurs by high blood glucose level in the body that may occur due to inability of body to produce insulin or respond to the formed insulin [1-2]. Diabetes is characterized by hyperglycemia, polyuria, polydipsia, polyphagia [3-4]. Diabetic retinopathy (DR) can be defined as damage to microvascular system in the retina due to prolonged hyperglycaemia that may lead to blindness [5-7]. It has been investigated that DR occurs both in type 1 and type 2 diabetes mellitus and has been shown that nearly all type 1 and type 2 diabetes leads to DR after prolonged duration of diabetes. Various signaling mechanisms have been found to be involved in pathogenesis of DR that include leukostasis and platelet activation, increased vascular permeability, NF- κ B, inducible nitric oxide Synthase (iNOS), COX, oxidative stress, ICAM-1, vascular endothelial growth factor (VEGF) and IL-1 β [7-10]. Various complications associated with DR have been noted that include vitreous hemorrhage, retinal detachment and glaucoma [11-12]. The review explains about the various signaling mechanisms involved in the development and progression of DR. In addition, strategies to treat DR have been discussed in the article.

CLASSIFICATION OF DR

DR has been considered as a disease of the retina which is the leading cause of acquired blindness in working adults in which the microvasculature of the retina gets severely damaged, the blood vessels swell and leak fluid, growth of new vessels initiates that ultimately lead to the detachment of the retina [13-14]. Moreover, DR has been detected clinically by the presence of visible ophthalmoscopic retinal microvasculature lesions in an individual with diabetes mellitus [15]. The DR can be classified in four types; mild non proliferative retinopathy, in which the retina swells

like balloon and is recognized as the earliest stage of DR; moderate non proliferative retinopathy, in which the blood vessels nourishing the retina get blocked; severe non proliferative retinopathy, in which the retinopathy spreads and blood vessels get blocked in several areas in retina; and proliferative retinopathy, in which the retina sends signals to trigger the growth of new blood vessels [15-16].

SIGNALING MECHANISMS INVOLVED IN DR

DR has been reported to be resulted from numerous biochemical alterations taking place in the vascular tissue of the retina [17-18]. The increased circulating levels of glucose accumulate in the retinal endothelial cells (ECs) and result in the activation of various biochemical pathways (Fig 1).

(a) Oxidative Stress: It has been noted that retina has high content of polyunsaturated fatty acids and has the highest oxygen uptake and glucose oxidation relative to any other tissue, which renders retina to be more susceptible to oxidative stress [19]. Additionally, the superoxide levels are elevated in the retina of diabetic rats and in retinal cells incubated in high glucose media [20]. The hydrogen peroxide content has been found to be increased in the retina of diabetic rats providing the evidence of oxidative stress in DR [21]. Further, it has been reported that the membrane lipid peroxidation and oxidative damage to DNA, the consequences of reactive oxygen species (ROS)-induced injury, are elevated in the retina in diabetes that further evidenced the role of oxidative stress in DR [22]. Moreover, in diabetes, the activities of antioxidant defense enzymes responsible for scavenging free radicals such as SOD, glutathione reductase, glutathione peroxidase and catalase are diminished in the retina [23].

(b) Aldose reductase and polyol pathway: Aldose reductase (AR) is an NADPH-dependent oxidoreductase which is primarily known for catalyzing the reduction of glucose to sorbitol, the first step in polyol pathway of glucose metabolism. It has been well reported that under the normal conditions, glucose utilization is primarily through the glycolytic pathway, whereas in diabetes excessive glucose is metabolized by the polyol pathway or AR enzyme. It has been noted that increased AR activity is implicated in the development of secondary diabetic complications [24]. The glucose flux through the polyol/AR pathway may lead to sorbitol accumulation and accompanying cellular damage [25]. The polyol pathway may also contribute to advanced glycation end product formation through methylglyoxal from increased glyceraldehydes 3-phosphate. The clinical trials also documented AR inhibition to be a potent therapeutic modality which was evidenced with one recent trial with AR inhibitor sorbinil, that showed slower rate of microaneurysms in the retina [26].

(c) Advanced glycation end products: It has been widely accepted that protein modification plays an important role in diabetic complications. Glucose participates in nonenzymatic glycation of proteins in order to produce advanced glycation end products (AGEs) [27]. It has been already reported that both AGEs and receptors for AGEs (RAGEs) have been localized to the retinal vasculature and vascular ECs [28]. Moreover, it has been demonstrated that AGEs lead to altered protein function, interfere with the extracellular matrix (ECM) function and cause elaboration of cytokines. The role of AGEs in the pathogenesis of DR is evidenced by the fact that the administration of exogenous AGEs to diabetic animals shows retinal pericyte loss [29]. Additionally, experimental studies in diabetic animals showed that a specific inhibitor of nonenzymatic glycation, aminoguanidine, prevented the retinal microaneurysms, acellular capillaries and pericyte loss in the diabetic dogs that further evidenced about the role of AGEs in the pathogenesis of DR [30].

(d) Protein kinase C activation: Protein kinases play modulatory role in transducing the adverse effects of hyperglycemia in the retinal vasculature, which was proved by the fact that the exposure of cultured ECs to high levels of glucose leads to the rapid induction of protein kinase family members [31]. Numbers of studies have reported about the activation of an important protein kinase, PKC in the framework of diabetes [32-33]. PKC isoforms which show significant activation in animal models of chronic diabetes include PKC α , β I, β II, γ , and δ with PKC β I and II show the highest level of induction in the retina of the diabetic animals [34]. PKC activation has been noted to cause a number of vascular effects leading to the progression of DR. Moreover, PKC has been shown to mediate glucose-induced EC permeability and ECM protein production. In addition, PKC has been involved in the expression of various growth factors and vasoactive factors and regulate cellular activity [35]. The modulatory role of PKC in the pathogenesis of DR has further been proved by several experimental and clinical studies which have been carried out with selective PKC β inhibitor, ruboxistaurin mesylate (LY333531). It has been reported in phase III clinical trials that ruboxistaurin showed a delay in the occurrence of moderate visual loss in patients with DR that evidenced the inhibitory role of PKC in the pathogenesis of DR [36].

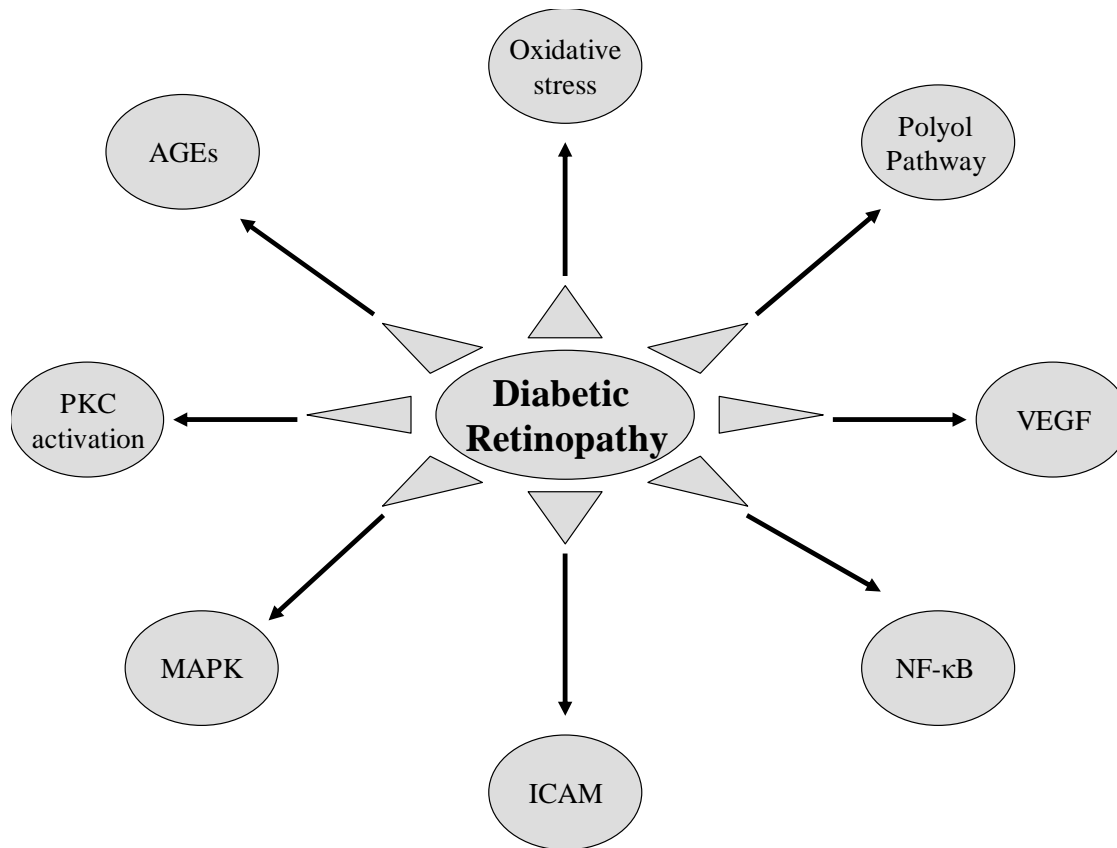


Figure 1. Diagram Showing Signaling Mechanisms Associated With DR.

AGE: Advanced glycation end-products; *PKC*: Protein kinase C; *VEGF*: Vascular endothelium growth factor; *MAPK*: Mitogen-activated protein kinase; *NF-κB*: Nuclear factor Kappa B; *ICAM*: Intracellular cell adhesion molecule.

(e) Mitogen-activated protein kinase activation: Studies have also demonstrated about the modulatory role of mitogen-activated protein kinase (MAPK) pathway in the development and progression of diabetic complications which, in part, is found to be dependent upon PKC activation [31]. MAPK activation proceeds through sequential activation of MAPKKK, MAPKK and MAPK [37]. It has been shown that glucose-induced ECM protein synthesis in ECs is mediated by the activation of MAPK. Further, it has been demonstrated that MAPK phosphorylation leads to activation of transcription factors NF-κB and activating protein-1 (AP-1) [31]. Moreover, inhibition of either MAPK or PKC has been found to normalize the effects of high levels of glucose that evidenced the modulatory role of MAPK in the pathogenesis of DR. Furthermore, inhibiting PKC in cells exposed to high glucose reduces MAPK activation which confirmed the important cross-regulation between PKC and MAPK [26].

(f) Leukostasis and platelet activation: It has been well understood that attraction and adhesion of leukocytes to the vascular wall are important components of inflammatory processes. The leukostasis has been found to be significantly increased in retinas of diabetic animals which might contribute to the capillary nonperfusion in DR [38]. The leukocyte stiffness has been reported to be increased due to hyperglycemia that contributes to the development of capillary nonperfusion in retinal vessels [8]. Moreover, leukostasis has been postulated to be a significant factor in death of retinal endothelial cells in diabetes [39]. In addition, another postulated cause of capillary nonperfusion in diabetes involves platelet activation. Platelet microthrombi are present in the retinas of diabetic rats and humans, and have been found to be associated with EC apoptosis [40].

(g) Nuclear factor-kappa B: NF-κB has been considered as a widely expressed inducible transcriptional factor which is an important regulator of many genes involved in mammalian inflammatory and immune responses,

proliferation and apoptosis [8]. Moreover, the DNA-binding experiments (EMSA) have demonstrated NF- κ B to be activated in retinal endothelial cells or pericytes exposed to elevated glucose concentration in retinas of diabetic rats [41]. The inhibition of proteins whose expression is regulated by NF- κ B has been noted to inhibit diabetes-induced degeneration of retinal capillaries provides evidence in support of the important role of NF- κ B in the pathogenesis of early stages of DR. Further, the compounds which are known to inhibit NF- κ B have been shown to inhibit the development of the retinopathy. Several different antioxidants which inhibit the development of capillary degeneration and pericyte loss in retinas of diabetic rats also inhibited the diabetes-induced activation of retinal NF- κ B that further evidenced the role of NF- κ B in the pathogenesis of DR [42]. Additionally, the low-intermediate doses of salicylates like aspirin and sulfasalazine, which inhibited NF- κ B activation in retinas of diabetic rats, also inhibited the capillary degeneration and pericyte loss in diabetic animals [43].

(h) Inducible nitric oxide synthase: It has been well reported that increased levels of nitric oxide products such as nitrotyrosine, nitrite and nitrate are found in retinas of diabetic animals [44-45]. In addition, the upregulation of inducible nitric oxide synthase (iNOS) has been found in the retinas of experimental diabetic rodents and patients in various studies [46-47]. The probable role of iNOS in the pathogenesis of DR has been suggested by the studies of aminoguanidine, a selective inhibitor of iNOS, which has been found to inhibit the diabetes-induced increase NO production and iNOS expression in retina [45]. Moreover, aminoguanidine has been noted to inhibit the development of the microvascular lesions of DR in various experimental animals that further evidenced the probable role of iNOS in the pathogenesis of DR. Furthermore, the role of iNOS in the development of the early stages of DR has been investigated directly using mice genetically deficient in iNOS which did not develop any structural or functional abnormalities seen in wild type diabetic mice [9].

(i) Cyclo-oxygenases: The induction of Cyclo-oxygenase-2 (COX-2) as well as increased production of prostaglandins (PGs) has been reported in the retinas of diabetic animals [48]. It has been shown that PGE2 production by retinas from diabetic rats was significantly inhibited by a selective COX-2 inhibitor, celecoxib, which suggested that COX-2 is primarily responsible for the diabetes-induced increase in retinal production of PGE2 in diabetic rats. In addition, COX-2 inhibition has been reported to inhibit the diabetes induced upregulation of retinal prostaglandins, increase in the retinal vessel permeability and leukostasis, and the death of retinal ECs cultured in diabetic-like concentrations of glucose, that further evidenced the role of COX-2 in the pathogenesis of DR [49-50].

(j) Intracellular cell adhesion molecules: The leukostasis due to the binding of white blood cells to intracellular cell adhesion molecules-1 (ICAM-1) is known to be increased in retinal blood vessels in diabetes [51]. The role of ICAM-1 in the pathogenesis of diabetes-induced retinal vascular disease has been confirmed by the fact that mice deficient in the genes for these proteins significantly developed fewer of abnormalities when compared to their wild-type controls that showed development of capillary degeneration and pericyte loss alongwith associated abnormalities including leukostasis, increased capillary permeability and capillary basement membrane thickening, thus providing evidence about the modulatory role of these inflammatory proteins in the pathogenesis of the DR [8,52].

(k) Vascular endothelium growth factor: VEGF, a proinflammatory molecule, has been well reported to possess a role in neovascularization and in increased permeability. Moreover, VEGF has been noted to accumulate in the retina early in diabetes [53-54]. The role of VEGF in the pathogenesis of DR has been confirmed by the fact that the repeated injections of high concentrations of VEGF in the eyes of nondiabetic monkeys resulted in the retinal damage, vascular tortuosity and microaneurysms [55]. In addition, clinical trials using anti-VEGF therapies have shown promising results against advanced stages of DR that further confirmed the modulatory role of VEGF in the pathogenesis and progression of DR [56-57].

(l) Interleukins-1-beta: It has been demonstrated that the levels of the proinflammatory cytokine, interleukins-1-beta (IL-1 β), are known to be increased in retinas from diabetic rats [58]. This contention has been supported by the fact that an intravitreal injection of IL-1 β or the exposure of retinal endothelial cells to the cytokine *in vitro* has shown to cause degeneration of retinal capillary endothelial cells. The role of IL-1 β in the pathogenesis of DR has been further studied using diabetic mice in whom the enzyme responsible for IL-1 β production was inhibited or in whom the IL-1 β receptor was deleted [8]. The inhibition of IL-1 β signaling using IL-1 β receptor knock-out mice protected the animals from diabetes-induced retinal pathology, confirming the fact that subsequent production of IL-1 β plays an important role in the development of diabetes-induced retinal pathology [59].

(m) Tumor necrotic factor-alpha: Tumor necrotic factor-alpha (TNF- α), another proinflammatory cytokine has a potential role in the pathogenesis of DR. It has been reported that the retinal levels of TNF- α are significantly greater than normal in diabetic rats [60]. Eterncept, a competitive inhibitor of TNF- α receptor, has been shown to block effects of TNF- α binding to cells. Moreover, Eterncept reduced leukocyte adherence in retinal blood vessels of diabetic rats when compared to controls, which further evidenced the role of TNF- α in the pathogenesis of DR [8].

COMPLICATIONS OF DR

DR has been well reported to involve the abnormal growth of blood vessels in the retina, the complication of which can lead to serious vision problems [61]. The first complication associated with DR is vitreous hemorrhage in which the new blood vessels bleed into a clear, jelly-like substance that fills in the center of the eyes. Moreover, the blood fills the vitreous cavity and completely blocks the vision in severe cases. The bleeding does not cause permanent vision loss and often clears up after a few weeks or months [62]. The second complication associated with DR is referred to as retinal detachment in which the abnormal blood vessels associated with DR stimulate the growth of scar tissue, which pull the retina away from the back of the eye, ultimately causing the spots floating in the vision, flashes of light or even severe vision loss [63]. Another DR-induced complication is neovascular glaucoma in which the leaking of blood vessels and abnormal growth of new vessels in the retina leads to the abnormal blood vessel growth in the iris, that can disrupt the normal flow of fluids in the eyes causing pressure to build up, ultimately leading to damage to the optic nerves and in severe cases, causes permanent damage to the vision [11-12].

STRATEGIES TO TREAT DR

DR remains to be a major cause of preventable blindness regardless of various advancements in ophthalmological care. Various advances in pharmacotherapy have been noted that show promise in the treatment of DR. Minocycline, a second-generation tetracycline, has been noted to inhibit the activation of retinal microglia induced by diabetes and prevent neuronal apoptosis in the retina of diabetic rats [58,64]. Moreover, the long-term administration of minocycline significantly inhibited the degeneration of retinal capillaries in diabetic mice and galactose-fed mice providing the potential of minocycline in the treatment of DR. Further, aspirin, sodium salicylate and sulphasalazine have been demonstrated to inhibit capillary degeneration in retinas of diabetic rats via inhibition of the NF- κ B pathway, suggesting their common action to inhibit DR [9]. Another class of the agents showing therapeutic potential against DR is corticosteroids which were confirmed by the fact that intravitreal injection of such steroids inhibited the diabetes-induced alterations in permeability of retinal vasculature and retinal edema in diabetic patients [65]. Benfotiamine, a lipid-soluble thiamine derivative, has been noted to significantly inhibit the development of acellular capillaries in retinas of diabetic rats [66]. Administration of PJ34, a potent PARP inhibitor, for nine months to diabetic rats significantly inhibited the diabetes-induced apoptosis of retinal microvascular cells and the development of early lesions of DR, providing a potential target for the treatment of DR. It has been suggested that VEGF is responsible for increase in retinal vascular permeability, causes breakdown of the blood-retinal barrier and results in retinal edema [67]. Additionally, VEGF is found to be upregulated in DR and hence, inhibiting VEGF can be a impending target in the treatment of DR [68]. Administration of Bevacizumab, a full-length recombinant humanized antibody, has shown potent activity against all isoforms of VEGF and thus, finds a way in the treatment of DR [69]. Another recombinant humanized antibody fragment, Ranibizumab, has shown activity against the isoforms of VEGF which is approved by FDA in the treatment of DR [70]. Another agent which showed a potential against vitreous hemorrhage is ovine hyaluronidase that has been shown to accelerate the clearance of vitreous hemorrhage in order to treat DR [71-72]. Pazopanib, a multitargeted tyrosine kinase inhibitor, has been recently reported to reduce diabetic retinal vascular leukostasis and leakage confirming its potential in the treatment of DR [73]. In addition, the effect of green tea on diabetes-induced retinal oxidative stress and proinflammatory parameters in rats has been investigated. The antioxidant enzymes superoxide dismutase and catalase showed decrease in activity in diabetic retinæ when compared to normal retina which suggests its potential role in the prevention and treatment of DR in humans [74].

CONCLUSION

Diabetes is a metabolic disorder characterized by hyperglycemia, polyurea, polydipsia and polyphagia. DR has been considered to be the complication of diabetes that may lead to permanent damage of eyes. Various signaling mechanisms like NF- κ β , TNF- α , IL-1 β , COX and iNOS have been involved in the pathogenesis of DR. Various strategies have already been reported to overcome the damage caused by DR. However, these strategies are not sufficient in order to have permanent prevention from the damaging effects of DR. Hence, further studies are needed in order to overcome the mortality and morbidity caused by DR.

REFERENCES

- [1] Weinert LS, Silveiro SP, Oppermann ML, Salazar CC, Simionato BM, Siebeneichler A, et al, *Arq Bras Endocrinol Metabol*, **2011**, 55: 435-45.
- [2] Crasto W, Khunti K, Davies MJ, *Drugs Today (Barc)*. **2011**, 47: 839-56.
- [3] Sandler S, Andersson AK, Barbu A, Hellerstrom C, Holstad M, Karlsson E, et al, *Ups J Med Sci*, **2000**, 105: 17-34.
- [4] Shewade Y, Tirth S, Bhonde RR, *J Biosci*, **2001**; 26: 349-55
- [5] Rema M, Pradeep R, *Ind J Med Res*, **2007**, 125: 297-310.
- [6] Furtado JM, Lansingh VC, Carter MJ, Milanese MF, Peña BN, Ghersi HA, et al, *Surv Ophthalmol*, **2011**, in press.
- [7] Tyagi M, Narayanan R, *Ophthalmology*, **2011**, 118: 2529-30.
- [8] Kern TS, *Exp Diabetes Res*, **2007**, 95103: 1-14.
- [9] Zheng L, Du Y, Miller C, Gubitosi-Klug RA, Ball S, Berkowitz BA, et al, *Diabetologia*, **2007**, 50: 1987-96.
- [10] Noda K, Nakao S, Ishida S, Ishibashi T, *J Ophthalmol*, **2012**; 2012: 279037.
- [11] Complications of diabetic retinopathy. Assessed from <http://www.nhs.uk/Conditions/Diabetic-retinopathy/Pages/Complications.aspx>, on Dec 2011.
- [12] Diabetic retinopathy. Assessed from <http://www.mayoclinic.com/health/diabetic-retinopathy/DS00447/DSECTION=complications>, on Dec 2011.
- [13] Frank RN, *N Eng J Med*, **2004**, 350: 48-58.
- [14] Aylward GW, *Eye*, **2005**, 19: 1115-8.
- [15] Kowluru RA, Chan PS, *Exp Diabetes Res*, **2007**, 2007: 43603.
- [16] Aiello LM, *Am J Ophthalmol*, **2003**, 136: 122.
- [17] Yun YW, Shin MH, Lee YH, Rhee JA, Choi JS, *J Prev Med Public Health*, **2011**, 44: 260-6.
- [18] van Eijk KN, Blom JW, Gussekloo J, Polak BC, Groeneveld Y, *Diabetes Res Clin Pract*, **2011**, in press.
- [19] Anderson RE, Rapp LM, Wiegand RD, *Curr Eye Res*, **1984**, 3: 223-7.
- [20] Cui Y, Xu X, Bi H, Zhu Q, Wu J, Xia X, et al, *Exp Eye Res*, **2006**, 83: 807-16.
- [21] Ellis EA, Guberski DL, Somogyi-Mann M, Grant MB, *Free Radical Biol Med*, **2000**, 28: 91-101.
- [22] Kowluru RA, Koppolu P, *Invest Ophthal Vis Sci*, **2002**, 43: 3287-91.
- [23] Haskins K, Bradley B, Powers K, Fadok V, Flores S, Ling X, et al, *Annals New York Acad Sci*, **2003**, 1005: 43-54.
- [24] Kinoshita JH, Nishimura C, *Diabetes Metab Rev*, **1988**, 4: 323-37.
- [25] Greene DA, Chakrabarti S, Lattimer SA, Sima AA, *J Clin Invest*, **1987**, 79: 1479-85.
- [26] Khan ZA, Chakrabarti S, *Exp Diab Res*, **2007**, 31867: 1-12.
- [27] Vlassara H, *Diab Metab Res Rev*, **2001**, 17: 436-43.
- [28] Stitt AW, He C, Vlassara H, *Biochem Biophys Res Commun*, **1999**, 256: 549-56.
- [29] Li ZP, Xu X, Huang YF, Zhu JF, Wang XJ, Hu HH, et al, *Graefe's Arch Clin Exp Ophthal*, **2003**, 241: 56-62.
- [30] Kern TS, Engerman RL, *Diabetes*, **2001**, 50: 1636-42.
- [31] Xin X, Khan ZA, Chen S, Chakrabarti S, *Lab Invest*, **2004**, 84: 1451-9
- [32] Ishii H, Koya D, King GL, *J Mol Med (Berl)*, **1998**, 76: 21-31.
- [33] Koya D, King GL, *Diabetes*, **1998**, 47: 859-6.
- [34] Idris I, Gray S, Donnelly R, *Diabetologia*, **2001**; 44: 659-73.
- [35] Pomeroy F, Allione A, Beltramo E, Buttiglieri S, D'Alù F, Ponte E, et al, *Diabetologia*, **2003**, 46: 416-9.
- [36] Aiello LP, Davis MD, Girach A, Kles KA, Milton RC, Sheetz MJ, et al, *Ophthalmology*. **2006**, 113: 2221-30.
- [37] Pearson G, Robinson F, Beers Gibson T, Xu BE, Karandikar M, Berman K, et al, *Endocr Rev*, **2001**; 22: 153-83.
- [38] Tamura H, Miyamoto K, Kiryu J, Miyahara S, Katsuta H, Hirose F, et al, *Invest Ophthalmol Vis Sci*, **2005**, 46: 1440-4.
- [39] Jousen AM, Murata T, Tsujikawa A, Kirchhof B, Bursell SE, Adamis AP, *Am J Pathol*, **2001**, 158: 147-52.
- [40] Boeri D, Maiello M, Lorenzi M, *Diabetes*, **2001**, 50: 1432-9.
- [41] Kowluru RA, Koppolu P, Chakrabarti S, Chen S, *Free Radic Res*, **2003**, 37: 1169-80.
- [42] Zheng L, Szabó C, Kern TS, *Diabetes*, **2004**, 53: 2960-7.
- [43] Kowluru RA, Engerman RL, Case GL, Kern TS, *Neurochem Int*, **2001**, 38: 385-90.
- [44] Abu El-Asrar AM, Desmet S, Meersschaert A, Dralands L, Missotten L, Geboes K, *Am J Ophthalmol*, **2001**, 132: 551-6.
- [45] Du Y, Smith MA, Miller CM, Kern TS, *J Neurochem*, **2002**, 80: 771-9.

-
- [46] Kowluru RA, *Curr Eye Res*, **2002**, 24: 123-8.
- [47] Kowluru RA, *Diabetes*, **2003**, 52: 818-23.
- [48] Ayalasomayajula SP, Amrite AC, Kompella UB, *Eur J Pharmacol*, **2004**, 13, 498: 275-8.
- [49] Joussea AM, Poulaki V, Mitsiades N, Kirchhof B, Koizumi K, Döhmen S, et al, *FASEB J*, **2002**, 16: 438-40.
- [50] Ayalasomayajula SP, Kompella UB, *Eur J Pharmacol*, **2003**, 458: 283-9.
- [51] Barber AJ, Antonetti DA, Kern TS, Reiter CE, Soans RS, Krady JK, et al, *Invest Ophthalmol Vis Sci*, **2005**, 46: 2210-8.
- [52] Joussea AM, Poulaki V, Le ML, Koizumi K, Esser C, Janicki H, et al, *FASEB J*, **2004**, 18: 1450-2.
- [53] Sone H, Kawakami Y, Okuda Y, Sekine Y, Honmura S, Matsuo K, et al, *Diabetologia*, **1997**, 40: 726-30.
- [54] Gerhardinger C, Brown LF, Roy S, Mizutani M, Zucker CL, Lorenzi M, *Am J Pathol*, **1998**, 152: 1453-62.
- [55] Tolentino MJ, McLeod DS, Taomoto M, Otsuji T, Adamis AP, Luty GA, *Am J Ophthalmol*, **2002**, 133: 373-85.
- [56] Arevalo JF, Fromow-Guerra J, Quiroz-Mercado H, Sanchez JG, Wu L, Maia M, et al, *Ophthalmology*, **2007**, 114: 743-50.
- [57] Starita C, Patel M, Katz B, Adamis AP, *Developments Ophthalmol*, **2007**, 39: 122-48.
- [58] Krady JK, Basu A, Allen CM, Xu Y, LaNoue KF, Gardner TW, *Diabetes*, **2005**, 54: 1559-65.
- [59] Vincent JA, Mohr S, *Diabetes*, **2007**, 56: 224-30.
- [60] El-Remessy AB, Al-Shabrawey M, Khalifa Y, Tsai NT, Caldwell RB, Liou GI, *Am J Pathol*, **2006**, 168: 235-44.
- [61] Imai H, Honda S, Tsukahara Y, Negi A, *Case Report Ophthalmol*, **2011**, 2: 314-18.
- [62] Pang C, Jia L, Jiang S, Liu W, Hou X, Zuo Y, *Diabetes Metab Res Rev*, **2011**, in press.
- [63] McHugh D, Gupta B, Saeed M, *Clin Ophthalmol*, **2011**, 5: 1543-8.
- [64] Wang AL, Yu AC, Lau LT, Lee C, Wu le M, Zhu X, et al, *Neurochem Int*, **2005**, 47: 152-8.
- [65] Kowluru RA, Odenbach S, *Diabetes*, **2004**, 53: 3233-8.
- [66] Hammes HP, Du X, Edelstein D, Taguchi T, Matsumura T, Ju Q, et al, *Nat Med*, **2003**, 9: 294-9.
- [67] Aiello LP, Bursell SE, Clermont A, Duh E, Ishii H, Takagi C, et al, *Diabetes*, **1997**, 46: 1473-80.
- [68] Viores SA, Youssri AI, Luna JD, *Histol Histopathol*, **1997**, 12: 99-109.
- [69] Yang JC, Haworth L, Sherry RM, *N Eng J Med*, **2003**, 349: 427-34.
- [70] Brown DM, Kaiser PK, *N Eng J Med*, **2006**, 355: 1432-44.
- [71] Kuppermann BD, Thomas EL, de Smet MD, Grillone LR, *Am J Ophthalmol*, **2005**, 140: 585.e1-15.
- [72] Schwartz SG, Flynn HW, *Exp Diabetes Res*, **2007**, 52487: 1-8.
- [73] Thakur A, Scheinman RI, Rao VR, Kompella UB, *Microvasc Res*, **2011**, 82: 346-50.
- [74] Kumar B, Gupta SK, Nag TC, Srivastava S, Saxena R, *Ophthalmic Res*, **2011**, 47: 103-8.