

ORIGINAL ARTICLE

Clinical Presentation and Outcome of Endoscopic Therapy in Patients with Symptomatic Chronic Pancreatitis Associated with Pancreas Divisum

Deepak Kumar Bhasin¹, Surinder Singh Rana¹, Rupinder Singh Sidhu¹, Birinder Nagi¹, Babu Ram Thapa¹, Ujjal Poddar³, Rajesh Gupta², Saroj Kant Sinha¹, Kartar Singh¹

Departments of ¹Gastroenterology and ²Surgery, Post Graduate Institute of Medical Education and Research (PGIMER). Chandigarh, India. ³Department of Pediatric Gastroenterology, Sanjay Gandhi Postgraduate Institute (SGPGI). Lucknow, India

ABSTRACT

Context The results of endoscopic drainage in pancreas divisum with chronic pancreatitis have been debatable. **Objective** To evaluate clinical presentation and long term results of endoscopic therapy in patients of calcific and non-calcific chronic pancreatitis with pancreas divisum. **Patients and Methods** Between 1996 and 2011, 48 patients (32 males and 16 females) with chronic pancreatitis and pancreas divisum were treated endoscopically. Patients were considered to have clinical success if they had resolution of symptoms and did not require surgery. **Results** All patients presented with abdominal pain and symptoms were present for 36.6±40.5 months. Pseudocyst, diabetes, pancreatic ascites, pancreatic pleural effusion, segmental portal hypertension and steatorrhea were seen in 13 (27.1%), 6 (12.5%), 3 (6.3%), 2 (4.2%), 2 (4.2%) and 1 (2.1%) patients, respectively. Ductal calculi and strictures were noted in 3 (6.3%) and 2 (4.2%) patients, respectively. In 47 patients, an endoprosthesis (5 or 7 Fr) was successfully placed in the dorsal duct. Following pancreatic endotherapy, 45/47 (95.7%) patients had successful outcome. The mean number of stenting sessions required to have clinical success was 2.6±0.9. One patient each had mild post ERCP pancreatitis, inward migration of stent and precipitation of diabetic ketoacidosis. Over a follow up of 2-174 months (median: 67 months), 12 out of 31 patients with pain only and no local complications (38.7%) required restenting for recurrence of pain and none of these patients required surgery. **Conclusion** Intensive pancreatic endotherapy is safe and effective both in patients with chronic calcific, as well as non-calcific, pancreatitis associated with pancreas divisum. It gives good long term response in patients having abdominal pain and/or dorsal ductal disruptions.

INTRODUCTION

Pancreas divisum (pancreas divisum) is the most common congenital variant of pancreatic ductal anatomy with an occurrence of approximately 10% (range: 1-14%) and occurs when the embryological ventral and dorsal buds fail to fuse [1]. Because of this anatomical variation, pancreatic juice is drained mainly through the accessory or minor papilla. Majority of patients with pancreas divisum are asymptomatic but a subset of patients may present with recurrent acute pancreatitis, chronic pancreatitis, or chronic abdominal pain. It has been proposed that in patients with

pancreas divisum when the minor papilla is critically small, a relative outflow obstruction to the pancreatic juice leads to high intraductal pressure, pancreatic ductal distension that leads on to pancreatitis [1, 2, 3]. This same hypothesis has led on to the development of endoscopic or surgical therapy for patients with symptomatic pancreas divisum. The goal of endoscopic or surgical therapy is to open up the minor papilla sphincter so as to relieve the relative obstruction to the outflow of pancreatic juice. Endoscopic therapy involves minor papillotomy or dorsal duct stenting or both [1].

There are a number of studies that have evaluated the efficacy of endoscopic therapy for pancreas divisum and most of them have shown that best results are obtained in patients with pancreas divisum and acute recurrent pancreatitis [4, 5, 6, 7, 8, 9, 10, 11, 12]. These studies have also concluded that the results of endoscopic therapy in patients with pancreas divisum and chronic pancreatitis are not good. However, there are very few studies that have evaluated endotherapy in patients with pancreas divisum with chronic

Received September 16th, 2012 – Accepted November 27th, 2012

Key words Cholangiopancreatography, Endoscopic Retrograde; Pancreatic Ducts; Pancreatitis, Chronic; Stents

Correspondence Deepak Kumar Bhasin

Department of Gastroenterology; Post Graduate Institute of Medical Education and Research (PGIMER); 1041, Sector 24-B; Chandigarh, 160 023; India

Phone: +91-172.272.5056; +91-172.271.5870

Fax: +91-172.274.4401

E-mail: deepakbhasin@gmail.com; dkbhasin@hotmail.com

pancreatitis or with chronic pain alone and most of the studies to date have relatively short follow-up or small sample size [4, 13]. Also there is scarcity of data on the efficacy of endotherapy in patients with pancreas divisum with chronic pancreatitis associated with various local complications like pseudocyst and pancreatic ascites and pleural effusion. In the current study from a single centre, we report clinical presentation and long term results of endoscopic therapy in 48 patients of calcific as well as non-calcific chronic pancreatitis associated with pancreas divisum who presented with pain and/or various local complications of chronic pancreatitis.

PATIENTS AND METHODS

Patients

All patients of chronic pancreatitis with pancreas divisum who underwent an attempted pancreatic endotherapy in our unit in the Department of Gastroenterology at Post Graduate Institute of Medical Education and Research, Chandigarh, India from January 1996 to March 2011 were retrospectively studied. All the patients selected for endoscopic therapy were either symptomatic with pain or had complications like pseudocysts, pancreatic abscess or pancreatic ascites/effusion. The diagnosis of chronic pancreatitis was made on the basis of clinical, biochemical and radiological investigations [14].

During the study period 48 patients (32 males, 16 females) with chronic pancreatitis and pancreas divisum were treated by pancreatic endotherapy. The mean age of these 48 patients was 32.6 ± 11.9 years (range: from 7 to 58 years).

Data Recording

A thorough diagnostic evaluation was done in patients with chronic abdominal pain and diagnosis of chronic pancreatitis was established if there was evidence of pancreatic calcification on abdominal X-ray and/or ultrasonography and/or abdominal computed tomography or there were characteristic ductal changes on magnetic resonance cholangiopancreatography (MRCP) and/or endoscopic retrograde cholangiopancreatography (ERCP). A detailed history specifically assessing the family history, alcohol consumption and presence and severity of abdominal pain were recorded. The absence of alcohol consumption was confirmed by repeated interviews of the patient as well as of the family members. Idiopathic pancreatitis was diagnosed if preexisting disorders likely to cause chronic pancreatitis (hypertriglyceridemia, primary hyperparathyroidism, abdominal trauma, and pancreatic duct stenosis secondary to surgery), hereditary pancreatitis (as determined by family history) and excessive alcohol consumption was absolutely ruled out [15]. Diagnosis of pancreas divisum was made on ERCP, when the main pancreatic duct was opacified via the minor papilla. Patients with pancreatic mass, pregnancy, presence of chronic cardiac, renal or pulmonary failure or patients not giving informed consent were excluded.

Diagnostic Procedure

Intravenous ciprofloxacin was administered for antibiotic prophylaxis. ERCP was performed by standard techniques using a TJF 130, 145 or TJF 160 (Olympus Optical Co. Ltd., Tokyo, Japan) side-viewing duodenoscopes under conscious sedation by intravenous midazolam and hyoscine butyl bromide was used to inhibit duodenal peristalsis. The cannulation of the minor papilla was attempted by using a tapered cannula and a guide wire. Secretin or methylene blue was not used. Initially, an attempt was made for contrast free pancreatic duct cannulation and if, that was not possible, minimal contrast was injected. Minor papillotomy, if required, was performed in a pull-type fashion by using a short-tip traction sphincterotome. In patients with chronic pancreatitis and pain, pancreatography findings were graded according to Cambridge classification [16]. Extracorporeal shock wave lithotripsy (ESWL) was done in patients with dorsal ductal calculi. The ductal strictures were dilated with bougie dilators or balloon dilators and this was followed by insertion of one or two endoprosthesis (5 or 7 Fr). When the stent was removed, the pancreatograms were obtained to assess the resolution of the strictures as well as to ensure good run-off of the contrast. In patients with pancreatic duct disruption, minimal contrast was injected after cannulation in order to confirm pancreatic duct disruption, defined by free extravasation of contrast outside the pancreatic ductal system as seen on fluoroscopy. Pancreatic duct disruption was defined as complete when the main duct upstream to the disruption was not opacified and as partial when the main duct was visualized upstream from the site of disruption. After confirming the ductal disruption, a 5 or 7 Fr nasopancreatic drain or stent was placed across the papilla in to the pancreatic duct by advancing it over a 0.025 or 0.035 inch hydrophilic guide wire (Jagwire; Microvasive Endoscopy, Boston Scientific Corp., Natick, MA, USA). An attempt was made to place the stent or nasopancreatic drain across the area of the disruption and if that was not possible it was placed as close as possible to the disruption.

Outcome Measures

The patients were regularly followed up in the outpatient clinic. Patients with pain were considered to have clinical success if they had resolution of pain and did not require surgery. Pre and post procedure analgesic usage was retrieved from the records and compared for analyzing success of the endotherapy. Following endoscopic therapy, patients were also asked about the impact of the endoscopic therapy on their daily activities and if they were better off following endotherapy. The stents were exchanged "on demand" or after one year and definite stent removal was attempted on basis of clinical and ERCP findings. In patients with complications the endoprosthesis was removed after clinical improvement as well as radiological resolution. At the time of the removal of

Table 1. Profile of patients with calcific and non calcific pancreatitis in patients with pancreas divisum.

	Calcific pancreas divisum (n=19)	Non-calcific pancreas divisum (n=29)	P value
Age (mean±SD; years)	33.3±11.3	32.1±12.3	0.236 ^a
Duration of symptoms (mean±SD ; months)	50.0±55.9	27.7±23.2	0.673 ^a
Males/females	13/6 (68.4/31.6%)	19/10 (65.5/34.5%)	1.000 ^b
Alcohol consumption	4 (21.1%)	6 (20.7%)	1.000 ^b
Diabetes	6 (31.6%)	0 (0%)	0.002 ^b
Stricture	2 (10.5%)	0 (0%)	0.152 ^b
Steatorrhea	1 (5.3%)	0 (0%)	0.396 ^b
Pleural effusion	1 (5.3%)	1 (3.4%)	1.000 ^b
Ascites	2 (10.5%)	1 (3.4%)	0.554 ^b
Pseudocyst	6 (31.6%)	7 (24.1%)	0.741 ^b

^a Mann-Whitney U-test^b Fisher exact test

endoprosthesis, a pancreatogram was obtained to document the healing of ductal disruption.

Chronic Pancreatitis Controls

The clinical profile of the 48 patients of pancreas divisum was compared with the clinical profile of 59 patients of alcohol related chronic pancreatitis (All males; P<0.001 vs. pancreas divisum) and 64 patients of idiopathic chronic pancreatitis (42 males, 22 females; P=1.000 vs. pancreas divisum) that were seen between June 1999 and June 2004.

ETHICS

The study was approved by the institutional ethics committee and an informed consent was obtained from all the patients. The study protocol conforms to the ethical guidelines of the "World Medical Association (WMA) Declaration of Helsinki - Ethical Principles for Medical Research Involving Human Subjects" adopted by the 18th WMA General Assembly, Helsinki, Finland, June 1964 and amended by the 59th WMA General Assembly, Seoul, South Korea, October 2008.

STATISTICS

Frequencies, mean, standard deviation and range were computed as descriptive statistics. Data were analyzed by means of the Mann-Whitney U-test and the Fisher's exact test by using the SPSS statistical package (version 10.1; SPSS Inc., Chicago, IL, USA). Two-tailed P values less than 0.05 were considered significant.

RESULTS

Nineteen (39.6%) patients had chronic calcific pancreatitis whereas 29 (60.4%) patients had chronic non-calcific chronic pancreatitis. In 10 (20.8%) patients, there was history of significant alcohol consumption, whereas in the remaining 38 (79.2%) patients of chronic pancreatitis with pancreas divisum, no other etiology of chronic pancreatitis could be identified. All the patients had abdominal pain with the mean duration of symptoms being 36.6±40.5 months. All the patients were on enzyme supplements and anti oxidants with no relief of the symptoms. The mean body mass index (BMI) of the patients was 18.6±2.4 kg/m². Pseudocyst, diabetes, pancreatic ascites, pancreatic pleural effusion, segmental portal hypertension and steatorrhea were seen in 13 (27.1%), 6 (12.5%), 3 (6.3%), 2 (4.2%), 2 (4.2%) and 1 (2.1%) patients, respectively. One patient with chronic calcific pancreatitis had presented with hematemesis and upon evaluation was found to have a pseudocyst along with a pseudoaneurysm of the gastroduodenal artery. On comparison of frequency of various complications between chronic calcific and non-calcific pancreatitis, we found that the frequency of diabetes was significantly higher in the calcific group: 6/19 (31.6%) vs. 0/29; P=0.002 (Table 1). There was no significant difference in the frequency of various other complications like pseudocyst, pancreatic ascites, pancreatic pleural effusion, segmental portal hypertension (calcific pancreas divisum: 1 (5.2%) vs.

Table 2. Comparison of various complications between alcohol related chronic pancreatitis, idiopathic chronic pancreatitis and chronic pancreatitis associated with pancreas divisum.

Complication	Pancreas divisum (n=48)	Alcoholic (n=59)	P vs. pancreas divisum	Idiopathic (n=64)	P vs. pancreas divisum
Age (mean±SD ;years){#14:}	32.6±11.9	41.5±9.9	<0.001 ^a	33.0 ±13.0	0.879 ^a
Calcification	19 (39.6%)	21 (35.6%)	0.693 ^b	30 (46.9%)	0.564 ^b
Pseudocyst	13 (27.1%)	28 (47.5%)	0.045 ^b	22 (34.4%)	0.537 ^b
Diabetes mellitus	6 (12.5%)	13 (22.0%)	0.217 ^b	15 (23.4%)	0.221 ^b
Ascites and/or pleural effusion	4 (8.3%)	11 (18.6%)	0.165 ^b	5 (7.8%)	1.000 ^b
Portal hypertension	2 (4.2%)	12 (20.3%)	0.019 ^b	11 (17.2%)	0.039 ^b

^a Mann-Whitney U-test^b Fisher exact test

non calcific pancreas divisum: 1 (3.4%) P=1.000), presence of stricture, and steatorrhea between calcific and non-calcific chronic pancreatitis.

On comparison of frequency of various complications between chronic pancreatitis with pancreas divisum alone and chronic pancreatitis with pancreas divisum along with alcoholism, the frequency of pancreatic ascites was significantly higher in the group that had history of significant alcohol ingestion: 3/10 (30.0%) vs. 0/38; P=0.007). There was no significant difference in the frequency of various other complications like pseudocyst, diabetes, pancreatic pleural effusion, segmental portal hypertension, pancreatic calcification and steatorrhea between the two groups (data not shown).

We also compared the clinical profile between the patients with pancreas divisum and both patients with alcohol related chronic pancreatitis and patients with idiopathic chronic pancreatitis. On comparison of frequency of various complications we found that the frequency of pseudocyst was significantly higher in patients of alcohol related chronic pancreatitis in comparison to patients with pancreas divisum (Table 2). However, the frequency of pseudocysts was not significantly different between idiopathic chronic pancreatitis and pancreas divisum. Also, portal hypertension was seen less commonly in patients with pancreas divisum when compared to patients with alcohol related and idiopathic chronic pancreatitis. There was no significant difference in the frequency of

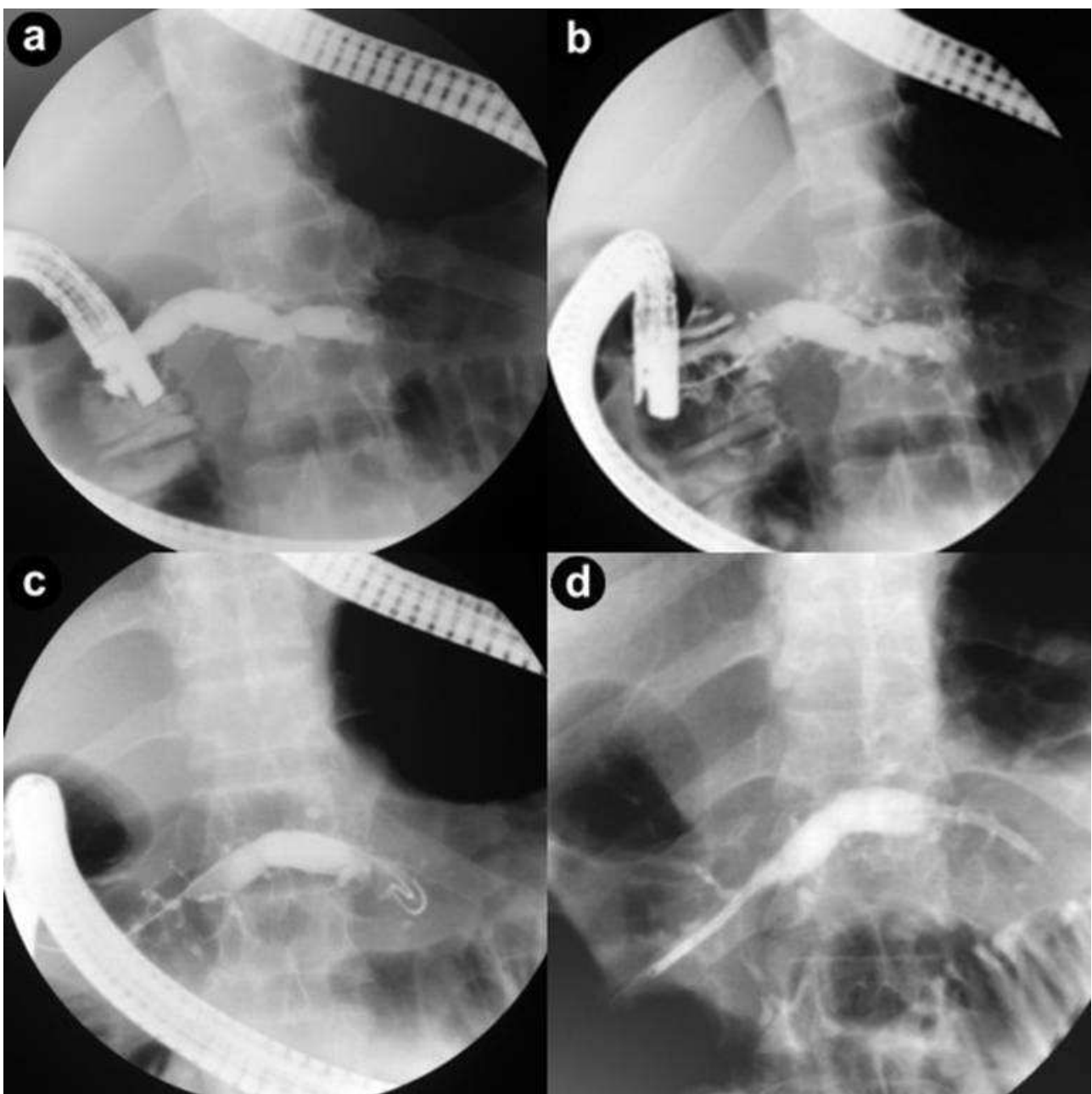


Figure 1. a. ERCP. Markedly dilated dorsal duct. b. ERCP. Deep cannulation of the dorsal duct. Markedly dilated dorsal duct with dilated side branches. c. ERCP. Guide wire negotiated into the tail end of dorsal duct. d. ERCP. Stent (7 Fr) placed in the dorsal duct.

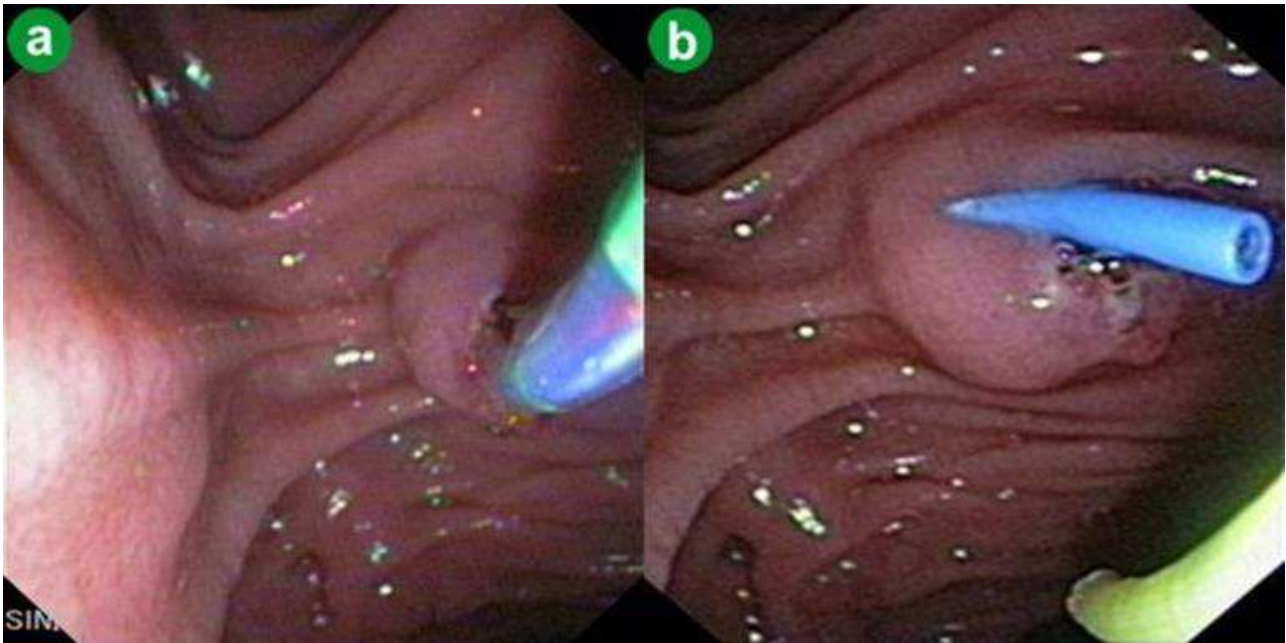


Figure 2. a. Minor papillotomy using pull type sphincterotome. **b.** Stent (5 Fr) placed after minor papillotomy.

various other complications like calcification, diabetes, pancreatic ascites and/or pancreatic pleural effusion. On ERCP, deep cannulation of the dorsal duct could be achieved in 47/48 (97.9%) patients and pancreatogram revealed severe and moderate ductal changes as per Cambridge classification in 25 (52.1%) and 23 (47.9%) patients respectively (Figure 1). Ductal calculi and strictures were noted in 3 (6.3%) and 2 (4.2%) patients, respectively. In one patient with ductal calculi as well as ductal stricture, deep cannulation could not be achieved and was treated surgically. In 47 patients, an endoprosthesis (5 or 7 Fr) was successfully placed in dorsal duct. In 12 patients (25.0%) a nasopancreatic drain was placed. All these patients in whom nasopancreatic drain was placed had large pseudocysts (greater than 6 cm) or pancreatic ascites/pleural effusion. Minor papillotomy was done in 7 patients (14.6%) (Figure 2) and extracorporeal shock wave lithotripsy (ESWL) in 2 patients (4.2%).

Outcome of Pancreatic Endotherapy

Following pancreatic endotherapy, 45/47 (95.7%) patients had successful outcome. Thirty-two patients (68.1%) had presented with chronic or recurrent pain only with no local complications. All these patients had significant abdominal pain and required narcotic analgesics at least once a week. In one patient, complete clearance of ductal calculi could not be achieved and he was treated with surgery. Remaining 31/32 (96.9%) of patients responded to pancreatic endotherapy and the mean number of stenting sessions required for success were 2.6 ± 0.9 . Of 32 patients, 24 patients (75.0%, including the one who had undergone surgery) were completely pain free and did not require analgesics whereas the remaining 8 patients (25.0%) had significant pain relief with none of the patients

(12.5%) requiring narcotic analgesics. Moreover, all the 31 patients felt that endoscopic therapy had a positive impact on their quality of life and post endotherapy they could perform their daily activities better as well as improved their attendance at the work place. One patient each had mild post ERCP pancreatitis, in ward migration of stent and precipitation of diabetic ketoacidosis as complication of endoscopic therapy [17]. The patient with post ERCP pancreatitis recovered uneventfully whereas inward migrated stent could be successfully retrieved with a snare after minor papillotomy. Diabetic ketoacidosis was successfully medically managed. After definitive stent removal, the 31 patients were followed up for 2-174 months (median: 67 months). Twelve (38.7%) patients required restenting for recurrence of pain and none of these patients required surgery. The remaining 19 patients remained pain free and three out of 31 (9.7%) developed diabetes on follow up.

In the 15 (31.3%) patients with dorsal duct disruption, there was complete resolution of pseudocysts or pancreatic ascites/pleural effusion in 14 patients (93.3%) within 8 weeks (range: 4-8 weeks). One of the 3 patients (33.3%) with pancreatic ascites had cardiac arrhythmia 48 hours after the procedure and succumbed to the cardiac illness. The 14 successfully treated patients remained asymptomatic on follow up ranging from 3 to 162 months.

DISCUSSION

Patients with pancreas divisum may develop recurrent acute pancreatitis, chronic pancreatitis, or chronic abdominal pain. Studies have demonstrated that decompression of the dorsal duct, either by minor papillotomy or stenting the minor papilla, leads to

objective improvement in symptoms in patients with pancreas divisum [4, 5, 6, 7, 8, 9, 10, 11, 12]. These studies have shown that the best results of pancreatic endotherapy are obtained in patients with acute recurrent pancreatitis. However, there are limited studies that have evaluated endotherapy in patients with pancreas divisum with chronic pancreatitis or with chronic pain alone and most of the studies to date have relatively short follow-up or small sample sizes [4, 13]. Also there is paucity of data on the clinical presentation of patients with chronic calcific and non-calcific chronic pancreatitis.

In the current study, like other causes of chronic pancreatitis, abdominal pain was the most common presenting symptom in patients with chronic pancreatitis and pancreas divisum. Local complications like pseudocyst, pancreatic ascites and pancreatic pleural effusion were seen in 13 (27.1%), 3 (6.3%) and 2 (4.2%) patients, respectively. When we compared the local complications in pancreas divisum patients with that seen in patients with idiopathic and alcohol related chronic pancreatitis, we observed lower frequency of local complications in patients with pancreas divisum in comparison to patients with alcohol related chronic pancreatitis and this observation needs further studies [18]. On comparison of frequency of various complications between chronic calcific and non-calcific pancreatitis associated with pancreas divisum, we noted that the frequency of diabetes was significantly higher in the calcific group whereas there was no significant difference in the frequency of various other complications like pseudocyst, diabetes, pancreatic ascites, pancreatic pleural effusion, segmental portal hypertension and steatorrhea between calcific and non-calcific chronic pancreatitis. This suggests that pancreatic calcifications are a marker of advanced pancreatic disease with more extensive pancreatic fibrosis and advanced destruction of pancreatic parenchyma occurring in calcific chronic pancreatitis and is similar to the profile seen in chronic calcific pancreatitis because of other etiologies [19].

In the present study pancreatic endotherapy was effective in about 95% of the patients with chronic pancreatitis and the response rates were similar in calcific and non-calcific chronic pancreatitis. In patients with abdominal pain and chronic pancreatitis, 31/32 (96.9%) of patients responded to pancreatic endotherapy with the mean number of stenting sessions required being 2.6 ± 0.9 . This response was long lasting after the stent removal in 19/31 (61.3%) patients. The abdominal pain recurred in 12/31 (38.7%) patients over a follow up period of 2-174 months and all these patients responded to repeat pancreatic endotherapy and none required surgery. Earlier studies had concluded that best results of endoscopic therapy in patients with pancreas divisum are obtained in patients with acute recurrent pancreatitis and the results of endoscopic therapy in patients with pancreas divisum and chronic pancreatitis are disappointing [4, 5, 6, 7, 8, 9, 10, 11, 12]. One of the limitations of our study is

that it is a single centre study with 48 patients of chronic pancreatitis associated with pancreas divisum. Boerma *et al.* reported their experience of pancreatic endotherapy in 16 patients with painful chronic pancreatitis and pancreas divisum with 10/16 (62.5%) patients responding successfully [4]. However, long lasting response (follow up of 3-24 months) was observed in only 5 (31.3%) of the patients and 5 (31.3%) patients required surgery [4]. Vitale *et al.* evaluated the efficacy of pancreatic endotherapy in 24 patients of chronic pancreatitis and pancreas divisum and reported that over a 12 year follow up period, 11/24 (45.8%) of patients required surgery [13]. Chacko *et al.* reported the results of pancreatic endotherapy in 20 patients with chronic pancreatitis and pancreas divisum presenting with abdominal pain [20]. There was clinical improvement in 8/19 (42.1%) of the patients with chronic pancreatitis. Borak *et al.* evaluated the results of pancreatic endotherapy in 22 patients with chronic pancreatitis and pancreas divisum and 10/22 (45.5%) of their patients had clinical improvement after pancreatic endotherapy with a follow up period of 16-116 months [21]. The above mentioned studies have shown immediate and long term response to pancreatic endotherapy in 30-60% of patients with chronic pancreatitis while in our study we found pancreatic endotherapy was effective in 95% of patients. Our better results could be because of different profile of patients. Majority of our patients with chronic pancreatitis and pancreas divisum had only dilated ducts with no strictures and calculi. This could have led on to improved results of pancreatic endotherapy.

Also, patients with chronic pancreatitis and pancreas divisum with local complications due to ductal disruptions responded successfully to pancreatic endotherapy. Fourteen (93.3%) patients with pseudocysts or pancreatic ascites/pleural effusion responded successfully to pancreatic endotherapy within 8 weeks (range: 4-8 weeks) and there was no recurrence on follow up. These results are comparable to earlier studies on pancreatic disruptions because of various etiologies that have shown pancreatic endotherapy via the transpapillary route to be effective in majority of the patients [22, 23, 24, 25, 26].

We observed in our study pancreatic endotherapy to be safe as complications were noted in only 3 patients (one patient each had mild post ERCP pancreatitis, inward migration of stent and precipitation of diabetic ketoacidosis). One patient with pancreatic ascites succumbed to unrelated cardiac illness. Other studies have also shown low complication rates of pancreatic endotherapy in patients with pancreas divisum [4, 5, 6, 7, 8, 9, 10, 11, 12, 27]. This low complication rate coupled with high success rates makes pancreatic endotherapy first-line treatment modality for patients with chronic pancreatitis secondary to pancreas divisum.

In conclusion, intensive pancreatic endotherapy involving minor papillotomy, dorsal duct stenting,

stricture dilatation and ESWL is safe and effective in patients with both chronic calcific as well as non-calcific pancreatitis associated with pancreas divisum and having abdominal pain and/or dorsal ductal disruptions with good long-term response.

Acknowledgement Part of this work had been presented at DDW 2010, New Orleans, LA, USA

Financial disclosures No financial disclosures and no financial assistance

Conflicts of interest no conflicts of interest

References

1. Lehman GA, Sherman S. Diagnosis and therapy of pancreas divisum. *Gastrointest Endosc Clin N Am* 1998;8:55-77. [PMID: 9405751]
2. Satterfield ST, McCarthy JH, Geenen JE, *et al.* Clinical experience in 82 patients with pancreas divisum: preliminary results of manometry and endoscopic therapy. *Pancreas* 1988; 3: 248– 253. [PMID: 3387418]
3. Richter JM, Schapiro RH, Mulley AG *et al.* Association of pancreas divisum and pancreatitis, and its treatment by sphincteroplasty of the accessory ampulla. *Gastroenterology* 1981; 81: 1104–1110. [PMID: 7286588]
4. Boerma D, Huibregtse K, Gulik TM, *et al.* Long term outcome of endoscopic stent placement for chronic pancreatitis associated with pancreas divisum. *Endoscopy* 2000;32:452-6. [PMID: 10863910]
5. Coleman SD, Gisen GM, Troughton AB, *et al.* Endoscopic treatment of pancreas divisum. *Am J Gastroenterol* 1994;89:1152-5. [PMID: 8053426]
6. Gerke H, Byrne MF, Stiffler HL, *et al.* Outcome of endoscopic minor papillotomy in patients with symptomatic pancreas divisum. *JOP* 2004;5:122-31. [PMID: 15138333]
7. Heyries L, Barthet M, Delvasto C, *et al.* Long-term results of endoscopic management of pancreas divisum with recurrent acute pancreatitis. *Gastrointest Endosc* 2002;55:376-81. [PMID: 11868012]
8. Kozarek RA, Ball TJ, Patterson DJ, *et al.* Endoscopic approach to pancreas divisum. *Dig Dis Sci* 1995;40:1974-81. [PMID: 7555452]
9. Lans JI, Geenan JE, Johanson JF, *et al.* Endoscopic therapy in patients with pancreas divisum and acute pancreatitis: a prospective, randomized, controlled clinical trial. *Gastrointest Endosc* 1992;38:430-4. [PMID: 1511816]
10. Lehman GA, Sherman S, Nisi R, *et al.* Pancreas divisum: results of minor papilla sphincterotomy. *Gastrointest Endosc* 1993;39:1-8. [PMID: 8454127]
11. Siegel JH, Ben-Zvi JS, Pullano W, *et al.* Effectiveness of endoscopic drainage for pancreas divisum: endoscopic and surgical results in 31 patients. *Endoscopy* 1990;22:129-33. [PMID: 2103724]
12. Bhasin DK, Sriram PV, Nagi B, Verma V, Singh K. Endoscopic stenting of minor papilla for symptomatic pancreas divisum. *Indian J Gastroenterol.* 1997;16:30-1. [PMID: 9167379]
13. Vitale GC, Vitale M, Vitale DS, Binford JC, Hill B. Long-term follow-up of endoscopic stenting in patients with chronic pancreatitis secondary to pancreas divisum. *Surg Endosc* 2007; 21: 2199-2202. [PMID: 17514389]
14. Etemad B and Whitcomb DC. Chronic pancreatitis: diagnosis, classification, and new genetic developments. *Gastroenterology* 2001; 120: 682-707. [PMID: 11172944]
15. Gabbriellini A, Mutignani M, Pandolfi M, Perri V, Costamagna G. Endotherapy of early onset idiopathic chronic pancreatitis: results with long term follow-up. *Gastrointest Endosc* 2002; 55:488-93. [PMID: 11923759]
16. Axon AT, Classen M, Cotton PB, Cremer M, Freeny PC, Lees WR. Pancreatography in chronic pancreatitis: international definitions. *Gut* 1984; 25: 1107–1112. [PMID: 6479687]
17. Bhasin DK, Sidhu RS, Bhansali A, Nagi B. Diabetic ketoacidosis in a patient with chronic calcific pancreatitis after minor papilla stent insertion. *Gastrointest Endosc.* 2004 ;59:440-3. [PMID: 14997152]
18. Bhasin DK, Singh G, Rana SS, *et al.* Clinical profile of idiopathic chronic pancreatitis in North India. *Clin Gastroenterol and Hepatol* 2009; 7: 594-99. [PMID: 19418608]
19. Bhasin DK, Rana SS, Chandail VS, *et al.* Clinical Profile of Calcific and Noncalcific Chronic Pancreatitis in North India. *J Clin Gastroenterol.* 2011; 45: 546-50. [PMID: 20962669]
20. Chacko LN, Chen YK, Shah RJ. Clinical outcomes and non endoscopic interventions after minor papilla endotherapy in patients with symptomatic pancreas divisum. *Gastrointest Endosc* 2008 68:667–673. [PMID: 18436218]
21. Borak GD, Romagnuolo J, Alsolaiman M, Holt EW, Cotton PB. Long-term clinical outcomes after endoscopic minor papilla therapy in symptomatic patients with pancreas divisum. *Pancreas.* 2009 ;38:903-6. [PMID: 19672208]
22. Bhasin DK, Rana SS, Udawat HP, *et al.* Management of multiple and large pseudocysts by endoscopic transpapillary nasopancreatic drainage alone. *Am J Gastroenterol* 2006; 101:1780-6. [PMID: 16780558]
23. Bhasin DK, Rana SS, Nanda M, *et al.* Endoscopic management of pancreatic pseudocysts at atypical locations. *Surg Endosc* 2010; 24: 1085-91. [PMID: 19915913]
24. Bhasin DK, Rana SS. Combining transpapillary pancreatic duct stenting with endoscopic transmural drainage for pancreatic fluid collections: Two heads better than one! *J Gastroenterol Hepatol* 2010; 25: 433-34. [PMID: 20370720]
25. Bhasin DK, Rana SS, Rawal P. Endoscopic retrograde pancreatography in pancreatic trauma: Need to break the mental barrier. *J Gastroenterol Hepatol* 2009; 24: 720-8. [PMID: 19383077]
26. Bhasin DK, Rana SS, Nanda M, *et al.* Comparative Evaluation of Transpapillary Drainage with Nasopancreatic Drain and Stent in Patients with Large Pseudocysts Located Near Tail of Pancreas. *J Gastrointest Surg.* 2011;15: 772-6. [PMID: 21359595]
27. Moffatt DC, Coté GA, Avula H, *et al.* Risk factors for ERCP-related complications in patients with pancreas divisum: a retrospective study. *Gastrointest Endosc.* 2011 73: 963-70. [PMID: 21392753]