

Acute Pancreatitis, Two Attacks with Normal Serum Amylase and Lipase - A Rare Case Report

Santo A Carnazzo¹, Andrea Musumeci², Rosalia Latino³, Paolo D Cannizzaro³

¹Departement of Biomedical and Biotechnological Sciences, University of Catania, Catania, Italy

²Radiodiagnostic and Radiotherapy Unit, University of Catania, Catania, Italy

³Department of General Surgery and Medical-Surgical Specialty, University of Catania, Catania, Italy

ABSTRACT

Context Acute pancreatitis is most commonly caused by gallstones or chronic alcohol use and accounts for more than 200,000 hospital admissions annually. Guidelines by the American College of Gastroenterology state that the diagnosis of acute pancreatitis requires the presence of two of the following three criteria: 1) abdominal pain consistent with the disease; 2) serum amylase and/or lipase greater than three times the upper limit of normal; 3) characteristic findings from abdominal imaging. Acute pancreatitis with normal serum amylase and/or lipase level in acute pancreatitis is an extremely rare occurrence. **Case report** Herein we present a case report with imaging-proven acute pancreatitis with normal serum amylase and lipase levels. **Conclusion** Acute pancreatitis is not always associated with increased levels of serum amylase and lipase and these markers can be misleading for the correct diagnosis.

INTRODUCTION

Although most cases of Acute Pancreatitis (AP) are caused by gallstones. Less often, the disease is contracted for alcohol abuse, following Endoscopic Retrograde Cholangiopancreatography (ERCP), in the course of hypertriglyceridemia and other causes. Despite the improvement of diagnostic technologies the etiology of AP remains unclear in about 20% of patients and is defined as Idiopathic AP (IAP). In accordance with the Atlanta classification, acute pancreatitis can be diagnosed if at least 2 of the following 3 criteria are fulfilled: abdominal pain; serum lipase or/and amylase activity at least 3 times the upper limit of normal; or characteristic findings of acute pancreatitis on contrast-enhanced Computed Tomography (CT) [1, 2].

Amylase and lipase, secreted by the acinar cells of the pancreas, are the most common laboratory markers used to establish the diagnosis of acute pancreatitis: amylase levels remain within abnormal range in 80-95% of cases; serum lipase levels typically increase in 95-100% of cases [3, 4].

Acute pancreatitis in the setting of a normal serum amylase or lipase is uncommon, normal serum amylase and lipase in the setting of acute pancreatitis is an extremely rare occurrence [5, 6, 7, 8, 9, 10, 11].

Nevertheless, both lipase and amylase alone lack the ability to determine the severity and etiology of acute pancreatitis; the reason for the variability of serum increases during AP is also uncertain [12]. Contrast-Enhanced Computed Tomography (CECT) is useful for the diagnosis of local complications with acute pancreatitis but its role as a prognostic tool remains controversial. Magnetic resonance imaging and Endoscopic Ultrasonography (EUS) should be reserved for patients in whom the diagnosis is unclear [1, 2].

CASE REPORT

A Fifty-five-year-old Caucasian female was admitted to the Emergency Department complaining nausea, vomiting, severe acute abdominal pain and distension. Her past medical history is significant for hypertension and hepatitis B. There was no documented history of hypertriglyceridemia. She was not an alcoholic. Her main laboratory results were: white blood cell count 8.200×10^9 (N 3 500–11 500 $10^9/L$); glycemia 154 (N 70–99 mg/dL); total bilirubin 0.7 (N 0.3–1.2 mg/dL); GGT 14 (N <38 U/L); alanine aminotransferase 39 (N <35 U/L); serum amylase 64 (N 28–100 U/L); serum lipase 21 (N 0–67 U/L); lactate dehydrogenase 257 (N 0–248 mmol/L); C-reactive protein 3.2 (N 0–5 mg/dL); creatinine 0.47 (N 0.51–0.95 mg/dL). Chest X-Ray and electrocardiograph were negative.

The patient was discharged home with a diagnosis of gastroenteritis. After 24 hours the patient was admitted

Received May 25th, 2019 - Accepted June 27th, 2019
Keywords Case Reports; Gallbladder; Pancreatitis
Abbreviations AP Acute pancreatitis; CECT Contrast-enhanced computed tomography; ERCP Endoscopic retrograde cholangiopancreatography

Correspondence Santo A Carnazzo
Department of Biomedical and Biotechnological Sciences
University of Catania, Catania, Italy
Tel + 095 7263231
Fax + 095 7263231
E-mail sacarna@unict.it

again to the Emergency Department with persistent and severe acute abdominal pain and distension.

Her main laboratory results were: white blood cell count $13,880 \times 10^9$; glycemia 182; total bilirubin 1.2; GGT 14; alanine aminotransferase 21; serum amylase 46; serum lipase 18; lactate dehydrogenase 465; C-reactive protein 5.5; creatinine 0.54.

Patient was admitted and was started on intravenous fluids and broad-spectrum antibiotics. On day three of hospitalization, patient developed worsening abdominal pain and distension, with blood pressure of 95/55 mmHg, with a heart rate of 95/min; the oxygen saturation was 78% on room air.

A CECT was performed and showed extensive pancreatic edema, especially involving the pancreatic head, and peripancreatic stranding; peripancreatic fluid collection are present, around the spleen, in the space of Morrison and in posterior cul-de-sac of Douglas (**Figure 1**).

Upon arrival to the department, the patient was mild responsive, tachypneic and hypotensive with a blood pressure of 90/55 mmHg, heart rate of 105/min; the oxygen saturation was 68% on room air, oliguria, severe abdominal pain.

Her main laboratory results were: white blood cell counts $7,200 \times 10^9$; glycemia 182; total bilirubin 1.1; GGT 14; alanine aminotransferase 21; serum amylase 52; serum lipase 18; lactate dehydrogenase 284; C-reactive protein 5.5; creatinine 0.59.

She underwent Magnetic Resonance (MR) imaging of abdomen that revealed normal findings of gall bladder, biliary tract, and common bile duct without gallstones and peripancreatic fluid collections (**Figure 2**).

Based on clinical presentation, laboratory results and radiological findings, the diagnosis of Severe Acute Pancreatitis (SAP) was made, like revised Atlanta classification [1]. The patient started on aggressive intravenous fluid hydration, pain management with diclofenac iv, intravenous meropenem, pantoprazole 40 mg iv, low flow O_2 therapy and bowel rest.

The patient had a good improvement in symptoms after 48 hours. On day six of hospitalization in our department, patient started oral nutrition and developed abdominal pain, associated with nausea and vomiting.

Notable values were: white blood cell counts $6,500 \times 10^9$; total bilirubin 1.6; GGT 75; alanine aminotransferase 107; serum amylase 51; serum lipase 50; lactate dehydrogenase 345; C-reactive protein 106; creatinine 0.46.

A repeat CT abdomen was done on day 6 due to persistent abdominal pain and it revealed worsening evidence of inflammation, normal findings of gallbladder, common bile duct was of normal diameter and intrabiliary duct dilatation was noted (**Figure 3**). She was treated with the same therapy at admission in our department.

On day nine of hospitalization patient had a good improvement in symptoms and EUS showed sludge of gallbladder. Patient was able to tolerate a regular diet and noted an almost complete resolution of pain, and

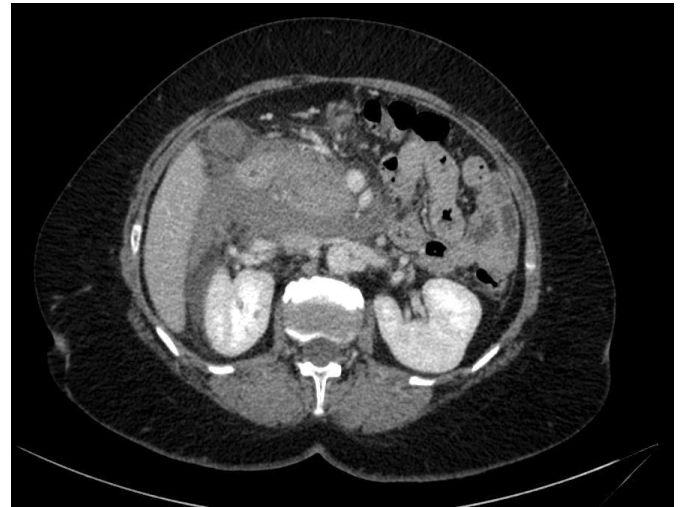

Figure 1. CECT of the abdomen showed inflammation of the pancreas, with peripancreatic stranding, and a small amount of surrounding fluid consistent with acute pancreatitis.

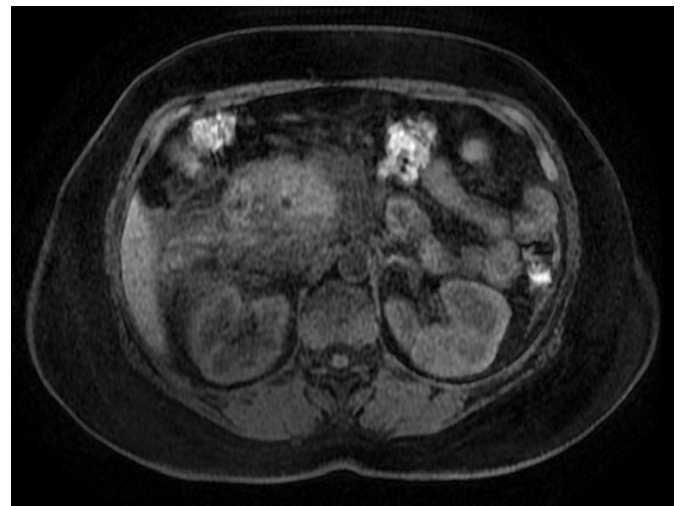


Figure 2. MRI of the abdomen showed prominent inflammatory changes surrounding the pancreas. Common bile duct measuring up to 5 to 5.5 mm. There are large heterogeneous fluid collections in the pararenal space of the right kidney.

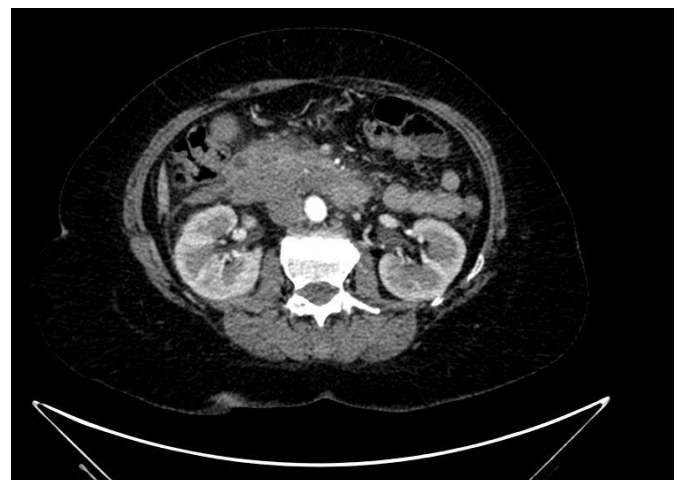


Figure 3. CECT showed reduction of edema of the head of the pancreas and reduction of fluid collections peripancreatic.

therefore was discharged home and a few months later she underwent surgery for cholecystectomy without any complications. Six months after cholecystectomy the patient no longer had similar symptoms.

DISCUSSION

Acute pancreatitis is a common disorder. Serum lipase level increases in 3 to 6 hours, peaks in 24 hours and remains elevated for one to two weeks. Nevertheless, few studies have suggested that serum lipase is a more sensitive biomarker of acute pancreatitis compared to serum amylase and several studies have reported a negative predictive value of serum lipase in diagnosing acute pancreatitis to be between 94 and 100 percent. However, serum amylase levels may remain within normal range in 20% of patients admitted with acute pancreatitis, serum lipase levels may remain within normal range only in 5% of patients with the same diagnosis [8].

This is an extremely rare case of acute pancreatitis with normal amylase and lipase levels. Our patient was admitted with a clinical picture consistent with acute pancreatitis despite normal lipase and amylase levels (Figures 4, 5, 6), condition that can be critical in the timely diagnosis and management of these patient.

In our case, patient’s lipase and amylase levels were within normal limits at admission and subsequent days with consequent delay in the diagnosis of AP and its treatment. Morbidity and mortality in AP are driven by early or late POF, following a delay in the diagnosis.

The patient had two attacks of AP and the lipase and amylase levels were within normal limits during both attacks.

The patient’s access to our emergency department during the painful attack excludes that the missed increase in amylase and lipase is related to a laboratory evaluation

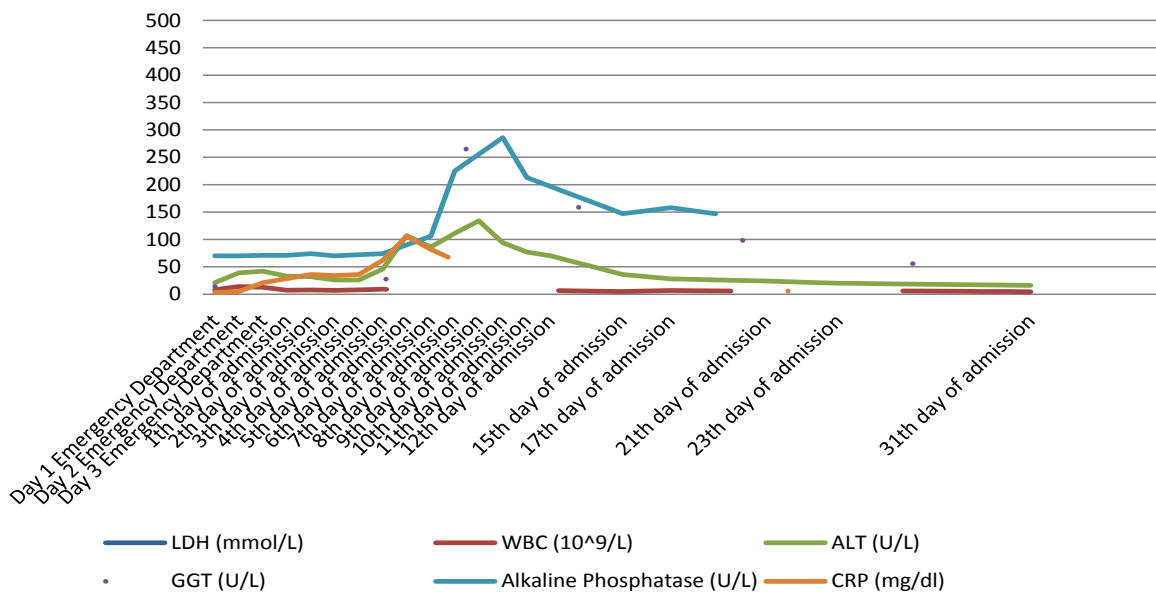


Figure 4. Serum level of lactate dehydrogenase, white blood cells, alanine aminotransferase, GGT, Alkaline Phosphatase and C-reactive protein.

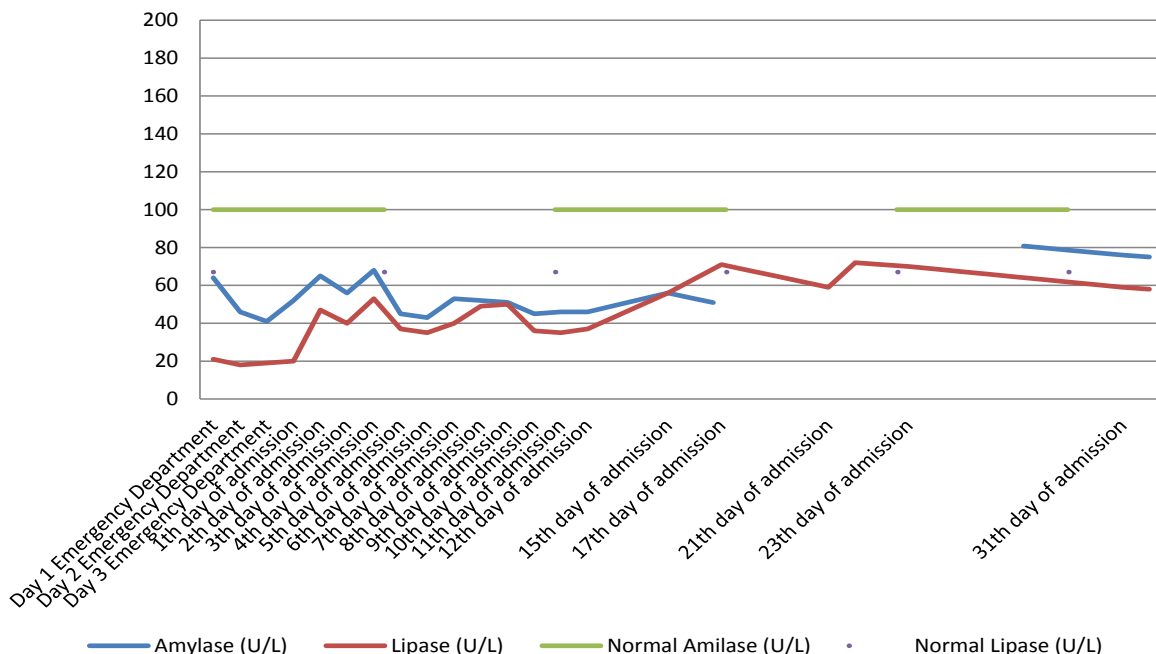


Figure 5. Serum level of amylase and lipase compared with normal serum levels.

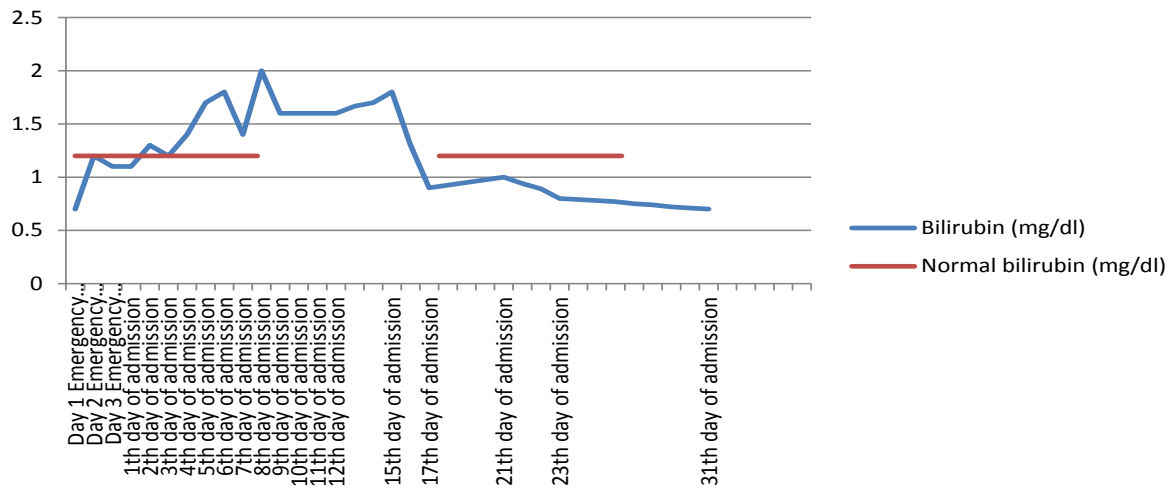


Figure 6. Serum level of total bilirubin.

delay. The non-use of alcohol related to the hepatitis B disease also excludes the possibility that the missed increase is linked to this habit of life. In our case report the lack of increase in amylase and lipase is repeated even during the second attack. The risk to visit a patient with SAP without increasing amylases and lipases is a delayed diagnosis or a serious unrecognized inflammatory disease with possible complications [13]. EUS should be performed in all patients whom the diagnosis of pancreatitis remains idiopathic if CECT and MRCP are negative [14].

CONCLUSION

In conclusions, serum amylase and lipase levels help in diagnosis making of most AP cases due to their simplicity and relative ease in measurement. Acute pancreatitis with normal serum amylase and lipase is a rare phenomenon which can occur. AP is not always associated with increased levels of serum amylase and lipase. If the clinical diagnosis is strongly suspected further imaging modalities may be helpful and CECT should be performed without delay.

Conflict of Interest

The authors disclose no financial relationships or conflict of interest relevant to this publication.

References

1. Tenner S, Baillie J, DeWitt J, Vege SS, American College of Gastroenterology. American College of Gastroenterology guideline: management of acute pancreatitis. *Am J Gastroenterol* 2013; 108:1400-1415. [PMID: 23896955]
2. Dupuis CS, Baptista V, Whalen G, Karam AR, Singh A, Wassef W. Diagnosis and management of acute pancreatitis and its complications. *Gastrointest Interv* 2013; 2:36-46.

3. Gomez D, Addison A, De Rosa A, Brooks A, Cameron IC. Retrospective study of patients with acute pancreatitis: is serum amylase still required?. *BMJ Open* 2012; 2:e001471. [PMID: 23002153]
4. Matull WR, Pereira SP, O'Donohue JW. Biochemical markers of acute pancreatitis. *J Clin Pathol* 2006; 59:340-4. [PMID: 16567468]
5. Shah AM, Eddi R, Kothari ST, Maksoud C, DiGiacomo WS, Baddoura W. Acute pancreatitis with normal serum lipase: a case series. *JOP* 2010; 11:369-372. [PMID: 20601812]
6. Clavien PA, Robert J, Meyer P, Borst F, Hauser H, Herrmann F, et al. Acute Pancreatitis and normoamylasemia. Not an uncommon combination. *Ann Surg* 1989; 210:614-620. [PMID: 2479346]
7. Alkhawam H, Catalano C, Zaiem F, Vyas N, Fabisevich M, Al-khazraji A. Acute pancreatitis with normal lipase and amylase enzymes. *J Investig Med* 2016; 64:941.
8. Neki NS, Shergill GS, Singh A, Rampal VK, Nizami S, Singh T. Acute Pancreatitis with normal amylase and lipase levels. *J Postgrad Med Inst* 2017; 31:199-202.
9. Cartier T, Sogni P, Perruche F, Meyniard O, Claessens YE, Dhainaut JF, et al. Normal lipase serum level in acute pancreatitis: a case report. *Emerg Med J* 2006; 23:701-702. [PMID: 16921084]
10. Rasheed T. Acute Pancreatitis with Normal Amylase and Lipase Enzymes. *J Med Sci Clin Res* 2016; 4:11730- 11734.
11. Ko K, Tello LC, Salt J. Acute Pancreatitis with normal amylase and lipase. *Med Forum* 2011; 4.
12. Keim V, Teich N, Fiedler F, Hartig W, Thiele G, Mössner J. A comparison of lipase and amylase in the diagnosis of acute pancreatitis in patients with abdominal pain. *Pancreas* 1998; 16:45-9. [PMID: 9436862]
13. Frank B, Gottlieb K. Amylase normal, lipase elevated: is it pancreatitis? A case series and review of literature. *Am J Gastroenterology* 1999; 94:463-9. [PMID: 10022647]
14. Kim DB, Paik CN, Song DS, Kim HA, Kim YJ, Lee JM. The role of endoscopic ultrasonography and magnetic resonance cholangiopancreatography in patients with acute pancreatitis after negative computed tomography findings of the etiology. *Pancreas* 2018; 4:1165-1171. [PMID: 30142119]