

DOI: 10.21767/2574-2817.100001

A Rapid and Successful Corticosteroid Based Approach Used to Treat Resistant Alopecia Areata Sisaipho in a 7 Years Old Egyptian Girl; When Pediatrics Equals Grace

Mina T Kelleni*

Pharmacology Department, Faculty of medicine, Minia University, Egypt

*Corresponding author: Mina T Kelleni, Pharmacology Department, Faculty of Medicine, Minia University, Egypt, Tel: (+20)1200382422; E-mail: drthabetpharm@yahoo.com

Rec date: Nov 14, 2016; Acc date: Nov 16, 2016; Pub date: Nov 28, 2016

Citation: Kelleni MT. A rapid and successful corticosteroid based approach used to treat resistant Alopecia Areata Sisaipho in a 7 years old Egyptian girl; when pediatrics equals grace. Ped Health Res. 2016, 1:1.

Editorial

In my career as a physician as well as a pharmacologist, I've encountered some pediatric patients that were so peculiar, and I've cherished the success with them more than with the adult ones, perhaps because after all who can resist the smile drawn on the face of a suffering child after he/she has been cured?

I want to share with you these two images that may illustrate further this feeling. Few months ago, parents came to my clinic with their 7 years old very shy girl, the reason was obvious; for 3 years they've tried hard to cure her auto immune alopecia areata (AA) consulting many dermatologists in vain, and recently a doctor tried multiple ultra violet sessions without any noticed improvement (Figure 1).




Figure 1 Sisaipho before and after one and two months of treatment, respectively.

I've previously mentioned that, unfortunately, for many reasons in some developing countries including Egypt, there may be a local approach to treat pediatric, and adult, patients that differs from the international one [1]. I've begun with gentle yet firm reassurance as should be in most of AA cases and I've described the case in my notebook as sisaipho; the term coined in 1996 by Munoz and Camacho to describe a peculiar type of AA which spares the peripheries of the scalp [2]. I've also told the parents that patience is needed as any

treatment regarding AA will take time and they were completely co-operative, I've prescribed 5 mg/kg monthly IM injections of methylprednisolone to be administered twice a day over three days [3]; monthly intradermal injections of triamcinolone 5 mg/ml simultaneously with daily topical application of betamethasone valerate lotion at night. What happened next amazed me before anyone else; an excellent hair growth was easily noticed during the early weeks of therapy (Figure 2). After only 2 months of treatment (Figure 3), I've even begun gradual reduction of the monthly IM steroid injections to be fully withdrawn at 6 months therapy by which I've stopped all the corticosteroids applied even the topical one. No relapse was noticed during or after corticosteroid withdrawal, the hair pattern reached to a nearly normal one at the end of the six months period and the previously shy girl is no longer intimidated to live a normal childhood without harassment from her colleagues laughing at the sight of her hair.

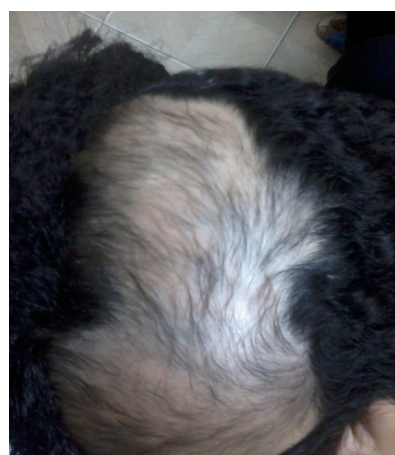

Figure 2 Sisaipho before and after one and two months of treatment, respectively.

I do believe that every time a physician helps a patient to find peace, some of this peace also enters the heart of physician and when this patient is a child, this peace can't be properly described by our earthy words. Pediatricians are

really being graced as you've this opportunity every day, please cherish it and be always proud you've chosen this wonderful career.

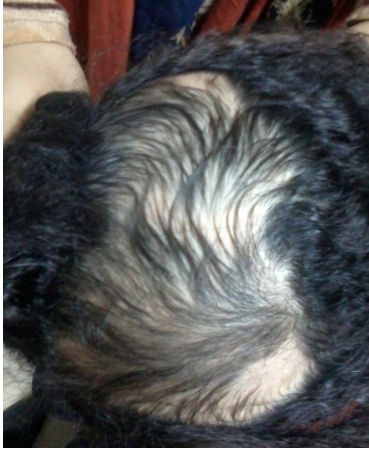

Figure 3 Sisaipho before and after one and two months of treatment, respectively.

References

1. Kelleni MT (2015) A Peculiar juvenile progressive systemic sclerosis case report: The Egyptian versus the international approach of treatment. *Gen Med* S2:005.
2. Munoz MA, Camacho FM (1996) Sisaipho: A new form of presentation of Alopecia areata. *Arch Dermatol* 132(10): 1255-1256.
3. James WD, Berger TG, Elston DM (2011) Diseases of the skin appendages. *Andrews diseases of the skin: Clinical dermatology*. Philadelphia, PA: Elsevier. Page 733.